

2015 Revision

Oman Medical Specialty Board Exam for General Dentists

Important Notices

This Paper contains the latest possible questions that you will or most likely face in the Omani Medical Specialty Board Exam for General Dentists. It's important to understand that this is a reference source and it's based on the experience of those who took the exam previously, none the less we are human and we can make mistakes, but we try our best to avoid it. – OziDent Team. Any statements written within brackets () are either incomplete, missing or not accurate.



Authors

- Original documents were by Dr. Maestro (d.somod@hotmail.com)
- Original Arrangement by unknown source
- Re-arranged by Dr. Mohsen S. Ozaibi (OziDent.com)

Contact

Please contact me at mohsen@ozident.com for further information or correction Aslo visit our website

Good luck

1) Staining of denture due to all except :

- A. Improper cleaning by patient
- B. Improper finishing and polishing
- C. Using heat acrylic resin during denture process***
- D. Porosity in denture base

2) To fabricate FPD in high temperature , pontic of upper 1st premolar give best illusion at the same time easy to clean is :

- A. Saddle pontic
- B. Modified ridge lab. ***
- C. Sanitary
- D. Ovate

3) Village with total population 1900, in 2007. 300 individuals were infected with certain disease in 2008, 150 individuals became infected. who the incidence and prevalence in 2008 :

- A. 150/1600 , 450/1900***
- B. 150/1900 , 450/1600
- C. 450/1600 , 150/1600
- D. 450/1900 , 150/1900

4) Obturation tooth with preiapical lesion in RCT , the obturation should :

- A. Obturation till superior end of lesion
- B. 0:5 - 1 mm shorter of radiographic apex***
- C. 1 mm beyond radiographic apex
- D. End at radiographic apex

5) Pt. came with RCT done before 5 years upon examination poor (failure) RCT , 1st choice of treatment is :

- A. Extraction
- B. Apicectomy
- C. Re-endo***

6) Endo failure mainly due to which organism :

- A. Staphylococcus onerosus
- B. Actinomycen and entrocohaus***
- C. Streptococcus

7) Best filling material of maxillary central incisor of deciduous is :

- A. Formacresol
- B. Iodoform
- C. Zinc oxide eugenol (ZOE)***

8) 8 years old child , trauma of maxillary incisor the material used for first visit Apexification :

- A. Ca(OH) + CMCP
- B. MTA***
- C. ZOE

MTA: Mineral Trioxide Aggregate.

9) CMCP contain :

- A. 65 % camphor , 35 % phenol***

CMCP: Camphor-Mono-Chloro-Phenol.

10) Sign of infection in oral cavity :

- A. Limited mouth opening
- B. High cervical lymph nodes
- C. Pain
- D. All of the above***

11) In incipient caries what is true :

- A. Impossible to reach to the pulp
- B. Integrant surface zone
- C. Preventive measures are indicated***

12) Which sentences are true regard to the caries :

- A. Most common type of caries is pits and fissure***
- B. Most common type of caries is proximal caries
- C. Fluoride is least effective in pits & fissure
- D. A & C

13) Pulp test for newly erupted tooth:

- A. Reliable
- B. unreliable***
- C. Same as permanent
- D. Un specific

14) Most common lesion associated with complete denture :

- A. Candida
- B. Sore mouth & ulcer ***
- C. Angular chilitis
- D. Resorbtion of ridge

15) Pt. have stone in submandibular duct , how to remove the sialolithiasis:

- A. lingual incision
- B. Trans oral incision***
- C. Sialendoscopy

16) Why not using metal in complete denture :

- A. Support & retention***
- B. Esthetic
- C. Stress distribution
- D. Easy relining

17) The most non irritant material is :

- A. Titanium***
- B. Gold noble alloy
- C. Chrome cobalt
- D. Nickel chrome

18) Geographic tongue is associated with :

- A. Low iron deficiency anemia **
- B. Erythematic
- C. Diabetic**
- D. Psoriasis**

19) The lesion well defined radio opacity (RO) with ached to the molar separated by radiolucent (RL) rim :

- A. Benign cementoplastoma***

20) Child have deciduas teeth not affected by floride but permanent teeth is affected , what is mean :

- A. Is dose not cross placenta***
- B. Calcification

21) What is the complex that lead to gingivitis or What micro organism initiate periodontal plaque :

- A. Orange complex
- B. Red complex
- C. Black complex
- D. Purple complex ***

22) Pt. have gunshot is result in lefort 2 , discharge from nose CSF , what is contain :

- A. High protein
- B. High glucose***

23) (T or F) pontic are classified depend on :

- A. Design (T)

24) Mental foramen :

- A. On the apex of root
- B. Near to the apex of root***

Note :(the mental foramen between lower 4 and 5 root)

25) 8 years old child with apical radiolucent ,the treatment is :

- A. Extraction
- B. Pulpotomy
- C. Pulpectomy ***

26) Lingual nerve supply :

- A. Mucous membrane of ant. 2/3rd of the tongue***
- B. Branches of distribution supply sublingual gland

27) How to do bleaching on RCT tooth :

- A. Micro abrasion
- B. Hydrogen peroxide (H₂O₂)***
- C. Crown
- D. Veneer

28) To decrease or prevent fracture of the restoration is placed on :

- A. Dentine***
- B. Enamel
- C. In thin base
- D. In thick base

29) Most common cyst in oral cavity is :

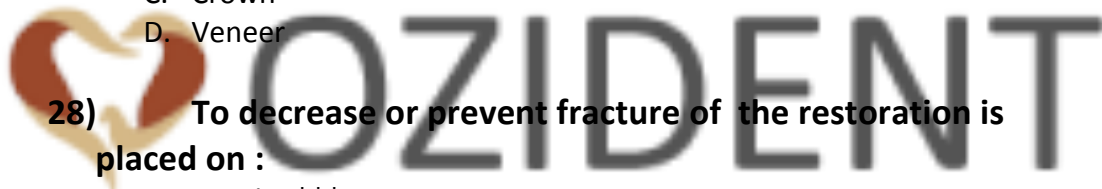- A. Radicular cyst***

30) Most retentive taperness of abutment is :

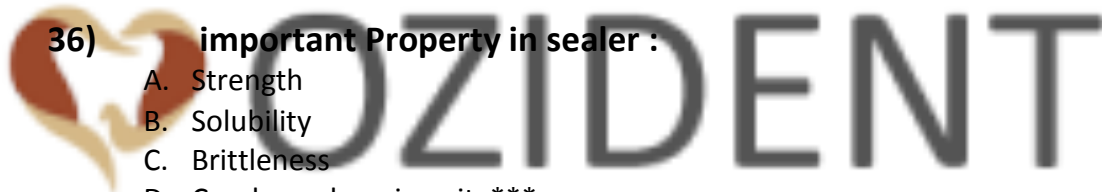- A. 6° ***

31) In 1945 USA ,early fluoridated water communnality case called :

- A. Michigan***



- 32) 8 years child, have no erupted teeth this case called :**
- A. Ectodermic dysplasia
 - B. Anadontia***
 - C. Hypodontia
 - D. Hyperdontia
- 33) 7 child , have severe pain & gross caries in 6 what is the treatment :**
- A. Pulpotomy
 - B. Pulpectomy ***
 - C. Direct pulp capping
 - D. Indirect pulp capping
- 34) 20 years old pt. , have severe pain on biting what is the diagnosis :**
- A. Complete root fracture
 - B. Partial fracture with pulp involvement
 - C. Partial fracture without pulp involvement***
- 35) Best material for impression :**
- A. Polyvinyl & polyether***
- 36) important Property in sealer :**
- A. Strength
 - B. Solubility
 - C. Brittleness
 - D. Condensed or viscosity***
- 37) Salivary gland disease (Swiss cheese) pt. in x-ray :**
- A. Adenoid cystic carcinoma ***
- 38) What is the nerve be supply lingual mucosa :**
- A. Buccal nerve
 - B. Inferior alveolar nerve
 - C. Lingual nerve***
 - D. Facial nerve
- 39) In 1 cusp how many pin :**
- A. 1***
 - B. 2
 - C. 3
 - D. 4



- 40) Broken condylar how to replace :**
A. Close reduction***
- 41) How we do follow up to endo :**
A. Pain on percussion
B. Size of lesion***
C. Sinus tract
- 42) Systemic fluoride dose depend on :**
A. Age
B. Wight***
- 43) Hard caries removed by :**
A. Spoon excavator
B. Bur high speed***
C. Bur low speed
D. Chisel
- 44) Mild florosis removed by the safest way :**
A. Micro abrasion
B. Bleaching ***
C. Veneer
D. Crown
- 45) Which part of instrument should be parallel during calculus removal :**
A. Shank***
B. Blade
C. Cutting edge
D. Handle
- 46) Ethics for human experimentation is from :**
A. ADA ethics
B. Hippocrates ethics***
C. Hammurabi ethics
- 47) During ext. lower mand. molar , the tooth fall down in pt. oral cavity, best way to retrieve it) :**
A. Addison
B. Allis
C. College pliers
D. Russian Tissue forceps***

- 48) How to prepare post space :**
- A. GG gates gladden
 - B. reamer
 - C. peeso reamer***
 - D. Diamond taper
- 49) Pt. with solitary bone cyst , the treatment is :**
- A. Excision
 - B. Incision
 - C. Remove lining mucosa*** or Curettage lining mucosa***
 - D. Marsupilization
- 50) How to retract flap of up. Lip with bland-end scissor :**
- A. metzenbaum scissor***
 - B. Dcans retract scissor
 - C. K- retract scissor
 - D. Iris- retract scissor
- 51) Over extend GP should be treated by :**
- A. Surgically***
 - B. Solvent
 - C. Ultrasonic scalier
 - D. Round bur rotary instrument
- 52) Brown discoloration up central , 4 years old with preiapical radiolucncy :**
- A. Pulpotomy
 - B. Pulpectomy
 - C. MTA
 - D. No ttt. ***
- 53) Pt. come with poor endo done 3 years ago the ttt is :**
- A. Re-endo***
 - B. Endo-surgery
 - C. Extraction
 - D. AB & analgesic
- 54) Best ttt for poor endo is:**
- A. Endo-surgery
 - B. Re-endo***
 - C. Extraction & implant
 - D. Antibiotics& analgesic

- 55) **Verrucous carcinoma:**
- A. Malignant lesion***
 - B. Benign lesion
 - C. Hypertrophic
 - D. Pre-malignant lesion
- 56) **Property of titanium that lead to fracture:**
- A. Axial fatigue***
- 57) **Regarding to the endo which is the correct :**
- A. Remove the cause of infection will allow to the healing***
- 58) **RCT is contra indication in all Except :**
- A. Vertical root fracture
 - B. Un-restored tooth
 - C. Insufficient periodontal support
 - A. Large preiapical area*** or Medically compromised pt. ***
 - D. Massive Resorbtion (internal-external)
- 59) **Rubber dam is contraindicated in :**
- A. Hyperactive pt.
 - B. Pt. with nasal obstruction***
 - C. Pt. with fixed appliance
 - D. Mentally retarded
- 60) **The 4th canal in maxillary first molar found in :**
- A. In palatal root
 - B. In MB root ***
 - C. In DB root
 - D. Between palatal and distao-buccal canal
- 61) **During intra-uterine life, embryo become fetus after :**
- A. 1st week
 - B. 1st month
 - C. 2nd month
 - D. 3rd month***
- 62) **After trituration amalgam , the mix should be placed within:**
- A. 1 min
 - B. 3 min ***
 - C. 5 min
 - D. 10 min

63) Syphilis 1st appear as :

- A. Multiple vesicles
- B. Erythematous reaching
- C. Ulcer***

64) 6 years old child has all his primary teeth except #74 (mand 1st molar) and #84 (mand right 1st molar)best space maintainer is :

- A. Fixed lingual arch
- B. Band and loop
- C. Bilateral band and loop***
- D. Crown and loop

65) Root canal material antiseptic cause protein coagulation :

- A. Sodium hypochloride
- B. Iodine potassium
- C. Formacresol***

66) Most common marginal failure of fixed prosthodontics is :

- A. Periodontal
- B. Pulpal
- C. Caries***
- D. Mechanical

67) Hybrid composite combination:

- A. Composite and Compomer
- B. Large molecule and small molecule of composite***

68) The posterior palatal seal of maxillary complete area can be detected by the following except :

- A. Hamular notch
- B. Fovea palatine***
- C. Anterior vibrating line
- D. Posterior vibrating line

69) Pt. complaining of sever spontaneous pain related to maxillary 6 no pain with percussion & respond to vitality test , diagnosis is :

- A. Irreversible pulpitis***
- B. Reversible pulpitis
- C. Acute apical periodontitis



- 70) Internal resorption :**
- A. Rarely in deciduous teeth
 - B. Initiated by odontoblast
 - C. Seldom confused with external resorption
 - D. It is usually asymptomatic***
- 71) When doing re-endo to remove GP , best method is :**
- A. Chemical
 - B. Mechanical
 - C. Heat
 - D. Chemically , mechanical & heat***
- 72) Pt. is 44 years old with periimplantitis, the best instrument used :**
- A. Carbon fiber***
 - B. Stainless steel
 - C. Ultrasonic scaler
- 73) 2 years old child came to your clinic with trauma caused intrusion of maxillary central incisors , what is your immediate ttt :**
- A. Repositioning
 - B. Extraction of both
 - C. Splinting
 - D. Make the pt. comfortable without touching the teeth***
- 74) Retention of amalgam by :**
- A. Convergence wall***
 - B. Divergence wall
- 75) Compomer is :**
- A. GI
 - B. Composite
 - C. Resin system with flour containing glass ***
- 76) Principles of using dental elevator are all except :**
- A. Widening of socket wall***
 - B. Wheel & axial
 - C. Lever
 - D. Wedging
- 77) Conservative cavity preparation of composite :**
- A. As amalgam cavity preparation
 - B. Extended amalgam cavity with bevel of E margin
 - C. Conservative cavity preparation***

78) 4 years old child , his first dental visit , behavior according to :

- A. Peer group influence
- B. Behavior shaping***
- C. Mother and father (or parents) introduce dental office
- D. Caring & friendly behavior of dental team

79) Supragingival calculus all except :

- A. White to white –yellowish
- B. Easily detached
- C. Has salivary component
- D. Hard and rough***

80) Disadvantages of plasticized gutta percha

- A. cause irritation to preiapical tissues***
- B. Prevent extrusion of GP
- C. Lead to osteo-clastic activity

81) Most biocompatible material :

- A. Titanium***
- B. Gold alloy

82) Tooth with questionable vitality method to check vitality :

- A. Cavity test***
- B. Vitality test
- C. Most important percussion
- D. Cavity test with L.A injection

83) Incision and drainage indicated in :

- A. Acute apical periodontitis**
- B. Swelling diffused and indurated
- C. Chronic suppurative peridontitis**
- D. Sinus tract

84) Most conservative method to lighten and whiting teeth :

- A. Micro abrasion
- B. Bleaching***
- C. Crown
- D. Veneer

85) 18 years old with healthy gingival , (differentiation) of epithelial keratinocytes:

- A. Loss of intraepithelial junction
- B. ↑ tono filaments
- C. Small size nuclei***

86) Pt. smokes 1000 cigarettes , heavy smoker and he has chronic gingivitis , the sign & symptoms of gingivitis :

- A. As much as former smoker
- B. More than
- C. Less than non-smoker***
- D. More than non-smoker

87) Pt. came with loss of 1ry teeth , consideration space maintainer depend mostly on :

- A. Time since tooth loss***
- B. Chronological age
- C. Early eruption of permanent teeth
- D. Delay eruption of 1ry teeth

88) Cavity varnish used to :

- A. Thermal protection
- B. Reduce tooth-restoration
- A. Prevent thermal damage of the pulp
- B. Decrease restoration leakage ***

89) All of the following cause xerostomia except :

- A. Disease in salivary gland
- B. Radio-therapy
- C. Wearing of denture***
- D. Antidepressant

90) During fabrication of lower crown in molar before seating of crown , surgeon do buccal grooves to :

- A. Prevent mesio-distal movement
- B. Structural durability
- C. Prevent movement (rotation) during seating***

91) Reduction for onlay minimum :

- A. 1 mm
- B. 1.3 mm
- C. 1.5 mm***
- D. 2 mm

- 92) Pt. has upper complete denture and lower anterior, what happen upper :**
- A. Upper loss bone anterior maxilla
 - B. Flapy ridge***
- 93) Best cement for crown :**
- A. Resin modified glass ionomer
 - B. Zinc phosphate ***
 - C. Resin
- 94) Osteoradionecrosis result of :**
- A. Radiation ***
 - B. Chemotherapy
- 95) Discolored anterior teeth with small RL area to tooth the ttt is :**
- A. Pulpotomy
 - B. Pulpectomy ***
 - C. Extraction
- 96) Material fatigue means :**
- A. Repeated loaded ***
 - B. Plastic deformation
 - C. Resistance to fracture
 - D. Plastic deformation with fracture resistance
- 97) Material used for fabrication mouth guard :**
- A. polyurethane***
- 98) Ideal cement thickness for crown in FPD in cementation :**
- A. 20-40 microns**
 - B. 20- 30 microns**
- 99) (PFM) Porcelain Fussed Metal reduction ideal :**
- A. 1:5mm***
 - B. 2mm
- 100) Pt. has lymphadenitis , fever persistence 2 days gray patch ulcer in gingiva and tongue, what does has :**
- A. Herpetic gingivostomatitis***

101) 2 months have ulcer in tongue by eruption of mandibular anterior teeth :

- A. bone nodule
- B. Herpetic gingivostomatitis
- C. Aphthous ulcers
- D. Riga- fade disease***

102) In preparation to avoid recession :

- A. Over contouring at gingival third
- B. Under contouring at gingival third
- C. Normal incline of tooth at gingival third***
- D. Place gingival margin 0,5 mm into gingival (crest or surface)

103) Pt. have an accident in aside he has infra orbital level of eyes , psudoptosis and pain to tempromfrontal suture and posterior open bit , which did he has :

- A. Gorlin fracture
- B. Le-fort 1 & 2
- C. Le-fort 3
- D. Isolated zygomatic fracture ***

104) All endo test except :

- A. False +ve
- B. False -ve
- C. Measure vitality***
- D. Asses vitality of pulp

105) (Tip of 20 file) :

- A. 0.2 at d1***

106) Regarding gingival cord :

- A. Apical
- B. Chemical
- C. Electrosurgical
- D. A & B ***

107) Group of people in the study followed up :

- A. cohort group***
- B. Prospective group

108) Factor will affect prognosis or success of disease outcome called :

- A. Confounding factor
- B. Prognostic ***
- C. Etiological
- D. Risk factor

109) Regarding epithelial rest of cells :

- A. Entrapment of epithelial cells cause granuloma***
- B. Disappear of completely during Dentinogenesis
- C. Decrease with age
- D. Increase with age

110) Permanent molar has deep caries with open apex :

- A. Apexification
- B. Direct pulp capping***

111) 8 years old boy, mechanical exposure for lower molar during excavation :

- A. Pulpotomy ***
- B. Ca(OH)
- C. Direct pulp capping
- D. Pulpectomy

112) Cause of hyper ventilation in clinic :

- A. Hypoxia
- B. Anxiety***
- C. ↑ co₂
- D. ↓ co₂

113) Nerve supply of lower facial mucosa at premolar & ant.

Area :

- A. Inferior alveolar nerve***

114) RCT pt. came after 1 week with pain RCT tooth , What to do :

- A. Re – endo***
- B. Analgesic
- C. AB
- D. Surgery

- 115) Best media for avulsed tooth :**
- A. Low fat milk**
 - B. Saliva**
 - C. Blood
 - D. Normal saline
- 116) Bottle caries mostly affect :**
- A. Upper ant. Teeth ***
 - B. Lower ant. Teeth
- 117) Most important before obturation is proper :**
- A. Cleaning and shaping***
 - B. Systemic Antibiotic
- 118) RCT since 8 years , no pain , during check up , PA RL lesion found , management is :**
- A. Re – endo ***
- 119) Which instrument is best to detection orifices :**
- A. Spreader
 - B. Endo files with curved tip
 - C. Explorer
 - D. Endo Explorer ***
- 120) 7 years old boy has trauma , exposure with superficial bleeding , ttt is :**
- A. Pulpotomy then final filling ***
 - B. RCT
 - C. Extraction
 - D. Pulp capping
- 121) 6 or 5 years old child (can't re-ttt) all his primary molars what your ttt :**
- A. Amalgam
 - B. Composite
 - C. SSC
 - D. GIC***
- 122) Patient with perforation. The dentist treat it with :**
- A. MTA***

- 123) Pt. with 2 wall defect :**
- A. Cancellous (buccal & lingual)or (Mesial & distal)bone graft***
 - B. Compact (buccal & lingual)or (Mesial & distal)bone graft
 - C. All bone the nearly the same result
- 124) Relining of the denture :**
- A. Add more acrylic to ↑ vertical dimension
 - B. Change the fitting surface of the denture***
- 125) The pt. commonly came complain from dray socket :**
- A. 24 h
 - B. 2 to 4 days***
 - C. 1 week
 - D. 2 weeks
- 126) Which type of restoration and cause wear to the opposing teeth :**
- A. Porcelain***
- 127) Which of these material chemically bond to the tooth surface :**
- A. G.I ***
 - B. Composite
 - C. Amalgam
 - D. All of the above
- 128) What is the best cement under composite with deep cavity of molar :**
- A. Zinc - oxide eugenol
 - B. Calcium hydroxide
 - C. GIC***
- 129) Varnish applied under amalgam at least how many layers :**
- A. 1 layer
 - B. 2 layers ***
 - C. 3 layers
 - D. 4 layers
- 130) The pt. have dull pain , swelling related to anterior tooth , there is RL in x-ray the diagnosis is :**
- A. Active preiapical periodontitis
 - B. Chronic periodontitis ***
 - C. Reversible pulpitis
 - D. Irreversible pulpitis

- 131) Pt. on corticosteroid therapy should take antibiotic because :**
- A. More susceptible to infection***
- 132) Bluegrass grass appliance used for :**
- A. Tongue thrusting
 - B. Mouth breathing
 - C. Thumb sucking***
 - D. Correct swallowing
- 133) Best time treating 4 years old child pt. in dental clinic :**
- A. Morning***
 - B. Afternoon
 - C. Evening
 - D. Late evening
- 134) Submandibular abscess drainage through :**
- A. Incision intra orally through mylohyoid muscle
 - B. Extra orally at the mandibular angle area***
- 135) Ectopic eruption of first permanent molar causing a resorption of distal root #E what is the best way for ttt :**
- A. Wait – observe
 - B. Extraction #E – distalization ***
- 136) Gingivectomy contraindication in :**
- A. Invasive bone surgery ***
 - B. Gingival inflammation
- 137) Condylar fracture , graft best taken from :**
- A. Iliac bone
 - B. Tibia
 - C. Costochondral rib bone ***
- 138) Pt. has pocket and want to increase attached gingival , the best flap done is :**
- A. Un displaced flap
 - B. Apical position flap***
 - C. Coronal position
 - D. Modified widmen flap

139) Pt. has fever a week ago coming to the clinic complaining from palatal nodule with yellow base histopathology shows that it is Sialometaplasia , what is ttt :

- A. AB course **
- B. Surgical removing
- C. Surgical removing with safety margin
- D. Non of the above**

140) During injection of diazepam for pt. has anxiety from dental ttt , pt. complain from burning sensation , what is the cause :

- A. Large size diameter needle
- B. Present of methylen in the solution***
- C. Present of in the solution

141) To accelerate setting time for alginate :

- A. Increase powder to water ratio
- B. Used cold water
- C. Increase mixing time***

142) 18 years old pt. the bacterial complex present in his mouth is :

- A. Red complex***
- B. Green complex
- C. Purple complex

143) Amalgam cusp reduction is :

- A. 1.5 mm**
- B. 0.5 mm
- C. 1 mm
- D. 1.5 – 2 mm **

144) 8 years old pt. with missing lower right primary 1st molar & lower left canine , 1ry , 2ry molars :

- A. Lingual arch***
- B. Bilateral band & loop
- C. Distal shoe
- D. Hawley appliance

145) Which type of bacteria is not motile :

- A. Staphylococcus aureus ***

- 146) In post & core all material used for pre-fabricate post except :**
- A. Stainless steel
 - B. Purely gold***
 - C. Fiber re-in forced resin
 - D. Zirconium
- 147) pt .with yellowish discoloration after RCT due to :**
- A. hemorrhage from pulp
 - B. leaving GP in pulp chamber
 - C. incomplete debridement of canal***
 - D. hemorrhage from canal +GP in pulp chamber
- 148) sharp bony specula of mylohyoid ridge , for declined construction , removal of these specula's by incision on crest of ridge should inject of which nerve :**
- A. Inferior alve. Nerve
 - B. mylohyoid nerve
 - C. lingual nerve ***
 - D. long buccal nerve
- 149) pt .with infection in sublingual , submandibular , submental area called :**
- A. Ludwig's angina ***
- 150) Squamous cell carcinoma is :**
- A. Mucosal epithelial lining***
 - B. Skin
 - C. Mucosal lining
 - D. Connective tissue
- 151) After scaling and RP , healing done by :**
- A. Long junctional epithelial***
- 152) Biological width is :**
- A. Epithelial attachment + connective tissue attachment***
- 153) Mesial shift , palatal of maxillary PM , palatal root will in relation to zygomatic arch :**
- A. Buccal
 - B. Lingual
 - C. Mesialy ***
 - D. Distally

154) To detect distal extension of post palatal seal :

- A. Tuberosity
- B. Tori
- C. Fovea palatine
- D. Vibrating line ***

155) Management of fractured tuberosity :

- A. Replace & suture***
- B. Replace & suture with intra-alveolar wire
- C. Remove & leave it to heal
- D. Remove & suture to heal with primary heal

156) Mastoid process is a part of :

- A. Temporal bone ***

157) Glenoid fossa in :

- A. Tempromandibular joint ***

158) For etching enamel use :

- A. 37% phosphoric ***

159) Taking phenytoin :

- A. Induced hyperplasia ***

160) Gingival enlargement :

- a. Dilantin phenytoin***

161) Doing Gingivectomy :

- A. Eliminate pseudo pocket***
- B. ↑ keratinized gingival

162) Gingivectomy indication for all except :

- A. Extensive alveolar removal ***
- B. Eliminate supra bony pocket
- C. Eliminate periodontal abscess

163) Open bite :

- A. Unilateral condylar fracture
- B. Bilateral condylar fracture***

164) Pt. with truisms, used technique akinosis in closed mouth technique needle to be :

- A. Gauge short needle
- B. Gauge ultra short needle
- C. 23 gauge long needle
- D. 25 gauge long needle ***

165) Acrylic teeth used in denture because :

- A. Acrylic dentures more wear resistance
- B. Acrylic denture ↑ good bonding to acrylic base ***
- C. Acrylic denture ↑ color stability
- D. Acrylic denture compressive strength

166) Porcelain margin used in or Porcelain finish margin is indicated in :

- A. Long span FPD
- B. Abutment used in RPD
- C. Single anterior crown ***

167) Tissue taken from one side to another of same pt. :

- A. Autograft ***
- B. Allograft
- C. Alloplast
- D. Xenograft

168) Important property of cement base under amalgam :

- A. ↑ modulus of elasticity ***
- B. Low modulus of elasticity
- C. ↑ modulus of elasticity & ↓ tensile strength

169) Best feature of sealant should be :

- A. Viscosity ***
- B. High retentive
- C. Resilient
- D. High strength

170) Pt. 2 ½ years old, upon exam selective caries in max. central incisor and 1ry molar what you should asked parents :

- A. Any one in family has same
- B. Do you give him milk bottle at night ***

- 171) What material Of the following is alloplast :**
- A. Ca phosphate ***
 - B. Iliac bone graft
 - C. Bone blend
 - D. Frizzed bone graft
- 172) Size 40 file means :**
- A. D 16 0.4
 - B. D 1 0.4 ***
 - C. ↑ from D1 – D16 by 0.4
 - D. Length ↑ by 0.4
- 173) Pt. came with severe pain from tooth with direct pulp capping , x-ray no PA , no pain with percussion but the pain with cold & hot lasting diagnosis :**
- A. Reversible pulpitis
 - B. Irreversible pulpitis ***
 - C. Acute apical peridontitis
 - D. Cracked
- 174) New recommendation is to finish amalgam :**
- A. 24 h***
- 175) Most important of using rotary instrument during instrumentation :**
- A. Irrigation***
 - B. Pro-crown taper
- 176) Functional cusp :**
- A. Palatal of upper & buccal of lower***
- 177) Composite matrix consist of :**
- A. Bis- GMA***
 - B. HEMA
 - C. Celluloid
 - D. Mylar
- 178) Angulations of the blade of scaler to stone during sharpening :**
- A. 50-60°
 - B. 70-80°***
 - C. 100-110°**

- 179) Mat. Used in x-ray injectable :**
A. T99 labeled iodine***
B. T99 labeled methyl diphosphate
- 180) After Gingivectomy , surface epithelial occurs :**
A. 3-5 days
B. 7-14 days***
C. 15-50 days
D. 20-22 days
- 181) Dog bite 10 years old boy on right side of his face the ttt :**
A. Leave it to heal
B. Place iodine to Make healing faster
C. Convert punch to laceration than suture***
D. Suture with resorbable suture
- 182) Pt. with diffuse swelling at lip , chronic histology tuberculosis giant cells the diagnosis is :**
A. cheilitis granulomatosa ***
B. T.B
- 183) Sterilization means killing of :**
A. Virus
B. Fungi
C. Bacteria
D. Virus , fungi , bacteria , bacteria spores***
- 184) Pt. with endocarditic, better prophylactic :**
A. Intra ligamentary L.A***
B. Remove of ortho band
C. Suture removal
D. Routine tooth brushing
- 185) In doing prep. For crown , axial reduction should be done in care to :**
A. Avoid injury adjacent tooth ***
- 186) Slowly growing lesion unilateral in mandibular , x-ray RO with RL :**
A. Cementoplastoma
B. Osteoma
C. Cemento-Ossifying fibroma***
D. Sarcoma

- 187) Open margin due to :**
- A. High temp. on casting
 - B. Over heating on casting
 - C. Under heating on casting ***
 - D. Short and wide space
- 188) Ugly duckling stage :**
- A. 6-8 y
 - B. 9-11y***
- 189) Correction of ugly stage :**
- A. By eruption of canine***
- 190) Eruption what teeth that cause ugly ducky stage is :**
- A. Premolar
 - B. Canine ***
 - C. Molar
- 191) Missing #36 , after 5 y most common feature :**
- A. Mesial drifting #37***
 - B. Over eruption of #26
- 192) 10 y old pt. came with no evidence of calcification of lower 2nd PM , what tell the pt. :**
- A. Root formed
 - B. Crown will be malformed
 - C. It will erupted within 6 months
 - D. Extract lower 2nd PM to allow 1st molar move for Mesialy ***
- 193) Nerve supply the gingival buccal tissue of lower primary molar , canine incisor is :**
- A. Long buccal
 - B. I.A.N***
 - C. Superior post. n
 - D. Lingual n
- 194) Amalgam is used in extensive cavities :**
- A. Cusp is supported by dentin ***
 - B. Cusp lost and thin supported wall
 - C. Cusps weak and resin in wall
 - D. Bevel and contra beveled
- 195) Pt. came complaining from bad odor although on exam , good oral H , no caries , ideal measurement of bad odor by :**
- A. Heliometers***

196) To reduce stress on abutment , they should be :

- A. Conical
- B. Multi-rooted***
- C. Fused
- D. Wide

197) Principle of tooth preparation in all except :

- A. Preserve tooth structure
- B. Supra gingival margin ***
- C. Resistance and retention
- D. Structural durability

198) potency file :

- A. Push the file apically to remove debris or remove any block at apex***
- B. Using circumferentially file to remove bio of lateral caries
- C. Recapitulation with bleach

199) Healing by 2ry intention :

- A. Return to its normal position
- B. Rapid healing and no scar
- C. Gap bet. Edge and minimal healing
- D. Gap bet. Edge with slow healing and scar***

200) CPR in unconscious pt. with cervical fracture :

- A. Collar preferred than manual co2***
- B. Manual preferred than collar co2

201) CPR pt. with spinal injury :

- A. Tilt head , chin left and jaw thrust
- B. Tilt head and chin left only
- C. Chin left only
- D. Jaw thrust only***

202) Brush cytology in apprehensive pt. :

- A. Bleeding and pain
- B. Only survey then used for biopsy***

203) How have to tack new record for young pt. :

- A. 5y after 1st app
- B. 7y from last record***
- C. 5y from last record
- D. When all pt. complete 18 y regardless of last records

- 204) Best surface finish on a composite resin restoration is created by :**
- A. The matrix band with no adds. Finish celluloid***
 - B. Silicon Carbide Fine Grit Discs
 - C. 12 fluted finishing burs
- 205) Pt. with Mesial eruption of maxillary 1st molar what to do to correct it's eruption :**
- A. Ligature wire ***
- 206) # 6 erupting Mesially, causing resorption of E :**
- A. Watch only
 - B. Band on E , let # 6 erupt
 - C. Ligature wire to direct eruption of #6 ***
- 207) Pt. with oral melanotic macula's what is the name of disease :**
- A. Peutz- jehgers syndrome***
- 208) Bonding agent for etched enamel we use :**
- A. Unfilled resin ***
 - B. Resin dissolve in acetone or alcohol
 - C. Primer with modified G.I
 - D. Primer and bonding agent
- 209) True or false :**
- A. Caries case failure of FPD (T)
 - B. If caries control , success rate of FPD will be high (T)
- 210) Name of elevator used to remove root apex :**
- A. Root pick ***
- 211) Question regarding to obturation :**
- A. Obturation technique affect sealer distribution in coronal $\frac{1}{3}$
 - B. Obturation technique affect sealer distribution in middle $\frac{1}{3}$
 - C. Obturation technique affect sealer distribution in apical $\frac{1}{3}$
 - D. No relation bet. Sealer distribution and location of root ***
- 212) Electrosurgery except :**
- A. Short cut
 - B. No local anesthesia***
 - C. No repeated

213) In Kennedy classification , all teeth present except upper maxillary incisor :

- A. Class4 ***
- B. Class1
- C. Class2
- D. Class3

214) Kennedy classification in prstho. All teeth lost except right and left canine :

- A. Class 1
- B. Class 1 modification 1***
- C. Class 4 modification 1

215) Lichen planus :

- A. white striae ***

216) Pontic design depend on part of pontic adjacent to edematous area, no relation bet. Pontic design and tissue response :

- A. Bothe T
- B. Bothe F
- C. 1st T 2nd F***
- D. 1st F 2nd T

217) Endo. Mistake RCT except :

- A. Ledge
- B. Dilacerations ***
- C. Brocken instrument
- D. Perforation

218) Odontogenic cyst :

- a. Arise from tooth tissue***

219) Pt. disk degeneration which type of innervating action to confirm diagnosis :

- a. Arthrography***

220) Blood clot suture to retain blood in its place :

- a. Figure 8 suture***
- b. Continuous suture

221) Endo surgery want to be done L.A long duration of action anesthesia :

- a. Bupivacaine***

222) Pt. who is beh. Co-operative in presences of parents :

- a. Benefit presence of parents***

223) Endo. Success by :

- a. Size of preiapical lesion***

224) Ortho and bone disease :

- a. Bio sulfonamide ***

225) Ca (OH)₂ Calcium hydroxide :

- a. To produce 2nd dentin***

226) List of services provided by dentist that may not include fees is :

- A. Deductible
- B. Insurance ***
- C. Manage care

227) hemiseptal bone defect :

- a. One wall defect***

228) Reversible hydrocolloid :

- a. Agar Agar ***

229) With age :

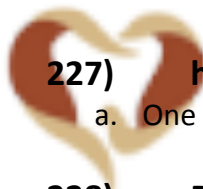
- a. ↓ size of pulp***

230) To check the finish line of preparation you hold the mirror opposite the tooth

- A. Upside down and ½ inch with one eye closed ***
- B. Upside down and ¼ inch with one eye closed
- C. Upside down and 1 inch with 2 eye
- D. Upside down and ½ inch with 2 eye

231) For ideal RCT spreader most be:

- A. 1 - 2 mm short of apex **or** 1-2 below working length ***
- B. At the apex
- C. Same as working length



OZIDENT

- 232) Gross fracture of amalgam due to :**
a. Cavity preparation not adequate***
- 233) Dentin hypersensitivity :**
a. Cover the exposed dentinal tubule***
- 234) Normal oral mucosa color interplay bet. :**
a. Keratinization & epith. Thickness & vascularity & melanin pigmentation***
- 235) Labial and buccal soft tissue of maxillary teeth innervated by :**
a. Anterior , middle , posterior superior alveolar nerve***
- 236) Occlusion in primary teeth :**
a. Flush terminal***
b. End to end
c. Mesial step
d. Distal step
- 237) Bevel in mandibular molar :**
a. Distal
b. Mesial
c. Buccal***
d. Lingual
- 238) 2 months pedo. Pt. , ulcer in ventral surface of the tongue during eruption of mand. Teeth what is the name of the disease :**
a. Erythema multiform
b. Aphthous ulcer
c. Riga fade disease***
- 239) To decrease the air bubbles during mixing of stone or investment , all true except :**
a. Keep spatula inside mixing***
- 240) T or F**
a. Caries dynamic in re-mineralization of demineralization , and it's reversible according to protein **(T)**
b. Gaudiness plan is two surface parallel to each other in abutment to allow easy insertion , abutment should be prepared or crowned **(T)**
- 241) Corrosion in low copper amalgam happen why :**
a. ↑ mercury***

242) Tooth germ from :

- a. Dental lamina***

243) Sterile the canal :

- a. Allow preiapical lesion to heal***

244) Pt. has hemophilia, fever, increasing in antibodies, lymphocytic, patches in soft palate & the line bet. Hard and soft palate :

- a. Thrombocytopenia***

245) Action of retraction cord is :

- a. Lateral and apical***

246) Color means :

- a. Chrome strength , saturation
- b. Hue red , yellow , green ,black ,purple***
- c. Value lightness

247) Coronal $\frac{2}{3}$ attaching ,which type of fibers :

- a. A cellular extrinsic***

248) Upon examination, dentist decided to do fine needle aspiration of keratocyst. the best gauge is :

- A. 19 gauge ***
- B. 20 gauge
- C. 25 gauge
- D. 30 gauge

249) Rebasing the denture means :

- a. Changing or adding the base
- b. Changing the tooth of the base
- c. Replace the base***
- d. Increasing the VDO by increase the thickness of the base

250) Caries in endemic it's means :

- a. Affect small population
- b. Has affect on countries with numerates***
- c. Present in area or region naturally

251) Open margin on crown what to do :

- a. Cover it with cement
- b. Replace crown ***
- c. Cover it with porcelain
- d. Cover it by burnishing the metal

252) Pedo. Pt. has difficulty on communicating with people and in learning , he push the food instead of swallowing it :

- a. Down syndrome
- b. Autism syndrome ***

253) What is not correct :

- a. Smear layer can be removed by MTAD
- b. Smear layer can be removed Completely by ETDA***
- c. Smear layer can be removed Partially by ETDA

MTAD, a new endodontic irrigant, has been introduced to fulfill these limitations. MTAD is a mixture of doxycycline, citric acid, and a detergent

254) The most important feature of luting cement :

- A. Tensile strength
- B. Compressive strength
- C. Resistance to solubility***

255) Fracture of pro-file due to which :

- a. Exide fatigue ***
- b. Rigidity
- c. Memory shape
- d. Torsion

256) Regarding cavity tests :

- a. Most common
- b. Non aggressive
- c. Last resort ***
- d. Use to detect preiapical condition

257) Dentist trim 1mm from size 3o cone because there is no friction , after trim there is friction , what is the size now :

- a. 28mm ,size28
- b. 29mm, size29
- c. 30mm,size 30
- d. 31mm,size 31
- e. 32mm,size32***

258) 45 days baby during examination we find asymptomatic, white, multiple nodules the mid of the palate. what is your diagnosis :

- a. Epstein pearls***
- b. Bohn nodules
- c. Mucus retain cyst
- d. herpetic

259) galgan and vermillion formula for florid :

- a. measure F in water in different area
- b. Measure F in water according to temp. of the area***
- c. asses age of the pt. according to the dentin
- d. measure F in tooth paste according to nature of water

260) Pedo. Pt. history of taking medication in the first 8 month of life. if the medication affect enamel hypoplasia , it will appear in which teeth :

- a. Max. & mand. Incisor & first molar***

261) FPD in mandibular molar , the preparation is short of lack of retention , we want to do provisional crown using zinc oxide eugenol cement what to do :

- a. Thick , creamy mix of the cement***
- b. Add petroleum to the cement
- c. Maintain dry field until cement set
- d. Remove hardened part of cement in interproximal area by using explorer

262) How to disinfect impression :

- a. Spray the tissue surface of impression + bottom of tray***

263) Both zincphosphat of polycarboxylate cement contain :

- a. Zinc powder ***
- b. Silicate powder
- c. Phosphoric liquid
- d. Polyacrylic liquid

264) What the cell in diabetic pt. affect so pt. is low immunity :

- a. Macrophage***

265) Periodontal ligament attach to which bone or Periodontal fiber inserted to which bone :

- a. Alveolar bone***

266) 45 y old pt. complain from soft, friable creamy color plaque. pt. had history of broad spectrum antibiotic due to urinary tract infection :

- a. Lichen planus
- b. Erythro plaques
- c. Condidiasis ***
- d. Herpes zoster

267) Maximum thickness of porcelain in FPD :

- a. 1mm
- b. 2mm***
- c. 3mm
- d. 4mm

268) How to check respiration if the pt. has respiratory problem :

- a. Pulse oximeter***
- b. Laser Doppler

269) Pedo. Pt. with vague pain and can't locate it what test used to locate pain :

- a. Anesthetic test***
- b. Test cavity

270) Doctor wants to check vitality of questionable tooth with large restoration , what used to check the vitality :

- a. Cavity test ***
- b. Cavity test with L.A
- c. Vitality test is done
- d. Tooth percussion test

271) The relationship bet. The working end of the hand piece and tooth surface called :

- a. Adaptation
- b. Activation **
- c. Angulations
- d. Accessibility**

272) Anesthetic test used to locate the pain in :

- a. Maxilla or mandible ***
- b. Across mid line
- c. Single tooth

273) Ethics :

- a. Veracity → honest
- b. Autonomy → consent form
- c. Just act → be fair in every situation
- d. Non maleficence → do not harm
- e. Beneficence → do good , caring
- f. Fidelity → do as you say you will do + respect confidentially

274) Pt. have tooth brown , discoloration skin , slowly growing , no oral manifestation histology degeneration of melanocyte :

- a. Oral melanotic macula
- b. Lentigo melanoma
- c. Junctional nevus***

275) Pt. with TMJ pain limited mand. Movement pain morning for 30 minutes which works and progress during day , limited joint space RG formation of Osteo..... pain divert head , clinically pain ausiculas area :

- a. Osteoarthritis ***
- b. Myofascial syndrome
- c. Rheumatoid arthritis

276) Pt. pedo. Caries yearly (new cases):

- a. Incidence***

277) Master apical file :

- a. Last file determined by diameter of apical***

278) MAF (Master Apical File) is :

- A. File used to reciprocate
- B. 1st file bind to working length
- C. File to measure working length
- D. Last file used to determine diameter of canal***

279) Ground glass appearance unilateral :

- a. Mono fibrous dysplasia***

280) Ground glass appearance bilateral :

- a. cherubism ***

281) Pt. with bilateral swelling of mandible , profound swelling of maxilla , cheeks are stroked with lower eye line depressed , x-ray radiolucent lesion with ↓ bone trabecular displacement of anterior teeth :

- A. Fibrous dysplasia
- B. Cherubism ***
- C. Basal cell nevus
- D. Giant cell granuloma

282) Bilateral balance for :

- a. Stability***

283) Shrinkage of porcelain after firing from normal :

- a. 1-5
- b. 5-10***
- c. 20-30
- d. 60

284) Water absorption of resin composite during composite doing :

- a. Discoloration
- b. Color instability ***
- c. Soft resin
- d. Decrease volume

285) Moisture contamination resin :

- a. Instability color***

286) High noble alloy minimum thickness of cast :

- a. 0.5***
- b. 0.3

287) Base under amalgam :

- a. High modulus of elasticity ***

288) Most common cement :

- a. Zn-ph***

289) All are (T) except :

- a. EDTA remove smear layer***
- b. EDTA 37%
- c. Na Oh + EDTA
- d. MTAB remove smear layer

290) Alginate imp. Disinfection :

- a. Rinse under tap water disinfect 10 sec pouring
- b. All of the above + plastic by 10 min***

291) Solvent to plasticized or (gutta percha) what is disadvantage :

- a. Apical irritation***

292) Pin after amalgam :

- a. Cold ***

293) Reverse bevel in inlay way :

- a. Resistance form***



- 294) **Finish margin all ceramic :**
a. Single anterior tooth***
- 295) **Maximum energy absorbed by material until fracture modulus of elasticity :**
a. Toughness***
b. Brightness
- 296) **Articulas hanue is :**
a. Semi adjustable articulator *** (adjustable ,angle foot incisor guide pin)
b. Sully adjustable articulator
- 297) **The color code for is file # 25 is :**
A. Yellow
B. Red ***
C. Blue
- 298) **Activation of scaliar angle bet. It and tooth :**
a. 14-45
b. 45-90***
- 299) **What lesion (calcification) :**
a. condensing osteitis***
- 300) **Lingual nerve supply :**
a. Submandibular gland
b. Sublingual gland
c. A+B***
- 301) **All contraindication of root canal except :**
a. Large periodontal lesion***
- 302) **Pt. makes root canal ttt 4 month radiolucent is there , pt. need :**
a. Follow up + x-ray***
- 303) **Material durable malleable :**
a. Gold***
- 304) **Cementation of veneer by :**
a. Resin***
- 305) **Why we did demineralization of alloplast by using hydrophilic of bone :**
a. To expose morphological protein***

- 306) Reparative dentin :**
a. Apposition in the pulp layer by irritation***
- 307) Mental attitude except :**
a. Angry ***
- 308) For best pit and fissure :**
a. Pumice stone***
- 309) CPR pt. fall down waiting area :**
a. 30/0.2 breath***
- 310) Narrow canal open by :**
a. EDTA***
- 311) Lesion brine cause disorder movement posture :**
a. Seizure
b. cerebral palsy***
- 312) Pt. extract premolar fall down mouth :**
a. College pliers***
- 313) After perio-surgery pack antibiotic :**
a. clindamycin ***
- 314) Contraindication of implant all except :**
a. Age ***
- 315) polysulphide what needed :**
a. Pour 1 h***
b. Pour 12 h
c. It need pressure
d. Need a special instrument to temper it
- 316) polysulphide :**
a. Need special tray for coolant***
- 317) Rebase :**
a. Change or add fitting surface***
- 318) What to prevent contamination restoration tech. :**
a. Rubber dam***
b. Cotton roll
c. Salivary ejector

- 319) Neonatal teeth erupt :**
- A. At birth
 - B. 0 – 30 days after birth 6 months ***
 - C. 6 years
- 320) Pt. generalized chronic periodontitis smoker sign and symptom :**
- a. Less gingivitis***
- 321) Reduction amalgam :**
- a. 1-1.5 mm
 - b. 1.5-2 mm***
 - c. 2-3 mm
- 322) Spading principle :**
- a. For selection of stainless steel***
- 323) Pedeo patient came to dental clinic have malnutrition and dirty clothes. this is :**
- A. Physically neglected***
 - B. Emotionally neglected
 - C. Physically abuse
 - D. Emotionally abuse
- 324) Pt. unerupted 1ry teeth upon OPG absence numerous permanent tooth :**
- a. Anadontia***
- 325) Pt. have periodontitis why do scaling and root planning :**
- a. To prevent further attachment loss***
- 326) Program of dental caries :**
- a. Water fluoridation***
- 327) No maleficence :**
- a. To do no harm***
- 328) It is responsibility of dentist :**
- a. He have to know general health of pt. to know medication***
- 329) All of this can be done by profithional dental team except :**
- a. Water fluoridation***

- 330) In – office bleaching :**
a. 38% hydrogen peroxide
- 331) Alveoloplasty :**
a. Obwes***
- 332) Ala of nose no x-ray :**
a. Naso labial cyst***
- 333) Large diastema between central incisors, you suspect supernumerary teeth. x-ray of choice :**
A. Occlusal ***
B. Bite wing
C. Preiapical
- 334) Best pedo behavior :**
a. Tell-show-do***
- 335) Extremely negative pt. during procedure :**
a. Strap ***
b. buboes
- 336) best AB for RCT :**
a. penicillin***
- 337) All need G.A except :**
a. Multiple caries successful dental ttt chair***
- 338) Where to put gold margin :**
a. Gingival 1/5 normal contour***
- 339) 4 y he loss #85 :**
a. Distal show***
- 340) 6y missing lower 4 and 4 :**
a. Bilateral band and loop ***
- 341) I.A.N :**
a. Posterior deviation from mandibular nerve***
- 342) Base of periodontal flab wider than coronal side because :**
A. Maintain blood supply ***

343) G.A indication and characteristic for all except :

- a. Young pt.
- b. SAS 1 and 2
- c. For convenience ***
- d. Pt. enter admitted and left same day

344) What the dentist make a procedure on the pt. the dentist cannot estimate breathing what should the dentist do for pt. because of breathing :

- a. Call CBR ***

345) 8 years old pt. swallowed 10 ml of 10 % fluoride what's the immediate action :

- A. Ingest milk ***
- B. Hospitalization

346) To treat Candida :

- A. Nystatin ***
- B. Tetracycline
- C. Miconazol

347) Ca(OH)₂ PH :

- a. 12.5 %***

348) Temporary filling anterior teeth with rampant caries :

- a. G.I.S ***

349) Carbide steel bur what the solution to sterilize with :

- a. 2% Na nitrite***

350) Squamous cell carcinoma consist :

- a. Lining Mucosal epithelium***

351) How to ttt fracture of symphysis by :

- a. Put plate infra coronal $\frac{1}{3}$ bone mono cortical screw ***
- b. Put plate infra coronal $\frac{1}{3}$ bone double cortical screw
- c. Put plate supra coronal $\frac{1}{3}$ bone mono cortical screw
- d. Put plate supra coronal $\frac{1}{3}$ bone double cortical screw

352) 5th generation adhesion bonding system :

- A. 1 MPA
- B. 15 MPA
- C. 30 MPA ***
- D. 60 MPA

353) Best floss is :

- a. Waxed nylon ***

354) Step done to compensate for metal shrinkage :

- A. Increase temp. of the metal
- B. Increase speed of the machine
- C. Put the investment in the oven to melt wax
- D. Silica bonded used in investment ***

355) Loss of enamel surface due to acidic substance called:

- A. Abrasion
- B. Erosion***
- C. Attrition

356) Irrigation during bone removal is to :

- A. Avoid heat generation ***
- B. To eliminate the smell of fresh bone
- C. To flush away debris

357) Best to remove discoloration of canal by :

- a. H₂O₂***
- b. Ether
- c. Sodium hypo chloride

358) Reciprocal arm resist denture movement of RPD what do resist :

- a. Retentive clasp***
- b. Major connector
- c. Minor connector
- d. Occlusal rest

359) Congenital missing lateral bilateral bad oral hygiene :

- a. RPD***
- b. Maryland
- c. Implant

360) Metal post not indicated for using it :

- a. 3-4 mm height remain
- b. 3-4 mm lost height of tooth
- c. 3 mm gutta percha remain
- d. Less than 25 % of tooth structure remain ***

361) Re ttt drug to hyperplasia of gingival :

- a. Nifedipine
- b. Phenytoin dilation ***
- c. Ca channel blocker

362) Pt. 7 y erupt 6 come to the antagonist of opposing :

- a. Clinical crown is $\frac{3}{4}$ anatomical crown +gingival sulcus on enamel +junctional epithelia of cementum
- b. Clinical crown is $\frac{3}{4}$ anatomical crown +gingival sulcus on CEJ +junctional epithelia of cementum***

363) What make glass ionomer different than composite :

- a. Solubility ***
- b. Wear resistance
- c. Coefficient of thermal expansion

364) Which thing is very important for caries :

- a. Artificial water fluoridation***

365) Dentist have a pt. had tuberculosis his hand want to clean it by :

- a. Chlorhexidine 0.1 – 0.2 %***
- b. Antimicrobial rap
- c. Non antimicrobial soap
- d. Alcohol

366) Chlorhexidine :

- a. Kill gram +ve and gram –ve***

367) Maxilla bone composed of maxilla and :

- a. Palatal bone***

368) Vibrating line :

- a. Junction bet. Hard and soft plate
- b. Junction bet. Movable and non movable***

369) Unacceptable attitude from dentist for pt. un cooperative physical disability :

- a. Send at home ***
- b. Tell- show - do
- c. Hand mouth tech.

370) 2y pt. with spot facial surface what to do ttt plane :

- a. Parent counseling
- b. Anticipatory guidance ***
- c. Nutritive analysis
- d. Caries examination

371) Prevalence is more :

- a. Pit and fissure is highest prevalence in all caries ***

372) Smokers :

| | Oral cancer | Control |
|-------------|-------------|---------|
| Smokers | 60% | 40% |
| Non smokers | 10% | 90% |

What is the percentage?

Adds ratio $90 \times 60 / 10 \times 40 = 5400 / 400 = 13.5$ ***

373) What is importance of epinephrine in anesthesia :

- a. Prolong vasoconstriction***

374) 28y old pt. multiple caries , chalky swollen gingival , 2-4 mm pocket , plaque increase index :

- a. Gingivitis
- b. Juvenile periodontitis
- c. High caries index*** → interproximal caries

375) Pt. 4 y extracted 1ry 2nd molar what space maintainer :

- a. Distal shoe***

376) Trying crown by prosthodontics pt. Say (seed on stuck) bet. My lower teeth :

- a. Tight contact***

377) Where to put contact area of FPD to relax papilla :

- a. Middle $\frac{1}{3}$
- b. Occlusal $\frac{1}{3}$ ***
- c. Cervical $\frac{1}{3}$
- d. Depend on opposing

378) Ca(OH)₂ application success is by :

- a. Doing dentin bridge over ***
- b. No pulpitis
- c. No pain

379) Tertiary dentin :

- a. At site of irritation ***
- b. Same to 2nd dentin

380) Occlusion of 1ry dentition at :

- a. distal aspect of mand 2nd molar***

381) Chemio Clara all are wrong except :

- a. Corrode instrument***

382) Major connector when to put in which phase :

- a. Examination
- b. Diagnosis and ttt. plane ***
- c. Ttt.

383) Endo. Failure :

- a. Perforation
- b. Strip
- c. Ledge
- d. All of the above***

384) In high incidence of a large and high growth community the need and prevention program is increased for:

- A. Periodontal disease
- B. Florosis
- C. Dental caries ***

385) Anesthesia is done before restoration procedure to :

- a. Vasoconstriction
- b. Vasodilatation
- c. Relief pain ***

386) The root canal sealer AH 26 contain :

- a. Epoxy resin***

387) Autogenic graft :

- a. Same pt. from one side to another side***

388) Lateral movement of occlusion (banned) movement can be seen greater in :

- a. Protrusive
- b. Open close
- c. Lateral ***
- d. Retrusive

389) Aging of pulp :

- a. ↓ Size of pulp***

390) Reparative dentine secretion mechanism :

- a. Irritation , stimulation***

391) Archon articulator :

- a. Adjustable condylar
- b. Curved condylar
- c. Movable maxillary part
- d. Adjustable mandibular part
- e. All of the above ***

392) Pain from cold sweet which is shot :

- a. Apical periodontitis
- b. Chronic periodontitis
- c. Dental sensitivity ***

393) Heat curing acrylic resin :

- a. Heat mandatory for polymerization***
- b. Heat is important to accelerate polymerization
- c. No need heat

394) Periodontal care outcome :

- a. Remove plaque***

395) Fissure sealant etching enamel :

- a. Dry bristle brush
- b. Aluminum air abrasion
- c. Pumices***

396) RL area beneath tooth and there is obturation where do we stop it :

- a. 0.5 – 1 mm before WL

397) To do x-ray prior extraction for :

- a. Anatomical important structure
- b. Bone
- c. A+B ***
- d. All of the above

398) Small access in the central lead to :

- a. Incomplete debridement***

399) Adult pt. has distal caries of anterior abraded incisal edge :

- a. Full crown
- b. All ceramic
- c. All veneer
- d. Partial veneer crown ***

400) Long span distal caries 1st molar the 2nd molar toward depth of caries box of 1st molar :

- a. Inter coronal restoration 1st molar
- b. Restoration 1st molar enamel of the 2nd molar ***
- c. Crown 1st molar separator 6,7 crown
- d. Provisional crown 6

401) Frankel classification of pedo is co-operative :

- a. Grade (4)***

402) Pedo Pt. enjoy dental ttt :

- a. Frankel classification 4***

403) Pt. pain less swelling mandibular in x-ray onion skin appearance :

- a. Anemia lymph cystic
- b. Burkitt lymphoma
- c. Pinborg
- d. Ewing sarcoma ***

404) Pt. carcinoma mandible 2cm inside ipsilateral involvement of lymphocytic , histopathology has lymphocyte :

- a. T1 N1 M0***
- b. T2 N2 M0
- c. T1
- d. T2

405) Pt. FPD bilateral pt. Occlusion class 3 :

- a. Bilateral balance
- b. Unilateral balance ***
- c. Reverse occlusion
- d. Muted protection

406) Pt. impression lower canine dentist want to do double :

- a. polyvinyl siloxane ***
- b. Additional
- c. Agar
- d. Polyether

407) Fissure sealant etching why :

- a. Chalky appearance to prepare tooth for sealant
- b. Clean debris
- c. Expose enamel tubules ***
- d. Increase restorative area

408) From where apical periodontal cyst :

- a. Series
- b. Malassez ***
- c. Hertwig

409) Amalgam restoration :

- a. Seated on sound dentin ***
- b. Seated on thick base
- c. Seated on thin base

410) Pt. has hard mass in maxilla slow gradual growing , no pain , drifted teeth , on histopathology shown speculated oven bone , x-ray shown ground glass appearance (shown chinless litters) what is the disease :

- a. Marble bone
- b. Mono fibrous dysplasia ***

411) Graft :

- a. Allo graft → one person to another person
- b. Alloplast →synthetic ca ph
- c. Xenoplast → animal to person

412) Def. :

- a. Arkon condylar past is attached to the lower member of articulator guidance , Glenoid fossa , mechanical fossa
- b. Non arkon condylar past is attached to the upper member of articulator (reverse TMJ)

413) Most difficult impaction :

- a. Mesio angular with fusel & conical roots
- b. Disto angular with fusel & conical roots
- c. Mesio angular with curved roots
- d. Disto angular with curved roots ***

414) Local contra indication extraction :


- a. Malignant site***
- b. Tooth crack fracture line
- c. Fracture line
- d. Radiotherapy
- e. Radiotherapy & malignant

415) Factor success implant except :

- a. Smoking
- b. ↑Caries index ***
- c. Radiotherapy
- d. Clinical works

416) Child will show equal number of primary and permanent teeth in his mouth (12 1ry 12 2^{ry}) at age of :

- a. 7.5
- b. 8.5
- c. 9.5
- d. 10.5
- e. 9-10 ***



OZIDENT

417) Most irritable cement for the pulp :

- A. Polycarboxylate
- B. Zinc phosphate ***
- C. Glass Ionomer

418) Bilateral firm swelling palate syndrome most common things the surgeon suspect to have in pt. :

- a. Paralysis , facial edema , fissured tongue
- b. Paralysis , uveitis , Xerostomia ***
- c. Paralysis ,ptosis ,Naso pharynx tumor
- d. Paralysis ,herpes zoster in ear

419) Decrease caries in developed country :

- a. Water fluoridation ***
- b. Dental health program

420) The accuracy of caries in year :

- a. Disease incidence ***

421) Most common cleft is :

- a. Cleft lip & palate***

422) Best cement durable thickness :

- a. Zn-ph**
- b. Resin **
- c. Modified resin glass ionomer

423) The cement material with uniform film thickness :

- A. Zinc oxide
- B. Resin **
- C. GI
- D. Zinc phosphate**

424) Bleeding gingival bad breath :

- a. ANUG***

425) Pt. physiological stress , smoker before 1 y he reported to school he has necrosis gingival , redness no attachment loss , treated by mechanical debridement and systemic antimicrobial thereby :

- a. Periodontitis
- b. ANUG***
- c. Lichen planus
- d. ANUP

426) Ulcer pharynx mouth and have desquamation body treated conjunctiva :

- a. Erythema multiform
- b. Stephen john syndrome ***

427) 28 years old what is the intermediate fiber lake in 25 adults:

- A. Gingival fiber ***
- B. Oblique
- C. Trans palatal

428) Best periodontal instrument to be good in function :

- a. Universal
- b. Offset blade
- c. Working blade centered long surface instrument
- d. Doubled angle ***

- 429) Which of the following is property of traditional G.I susceptible to dehydration over life time moisture :**
- Susceptible To dehydration + no free monomer***
- 430) To plane facial and lingual wall :**
- Enamel hatched ***
 - Straight chesil
- 431) Root pouched max. sinus:**
- Palatal root of 6***
- 432) Instrument used to retract cheek + flap at same is :**
- Minnesota retractor ***
 - Weirder
- 433) Pt. have nasal fracture which forceps is use to reposition , or impact nasal bone :**
- Walsham or arch forceps***
- 434) Finish line FPD porcelain fuse metal with metal collar :**
- Chamfer***
- 435) Amount of epinephrine to be given safety in pt. (.....) :**
- 0.01-0.02***
 - 0.02-0.03
- 436) About custom tray special tray all are true except :**
- Semisolid to be easily removed ***
 - Space to make mouth impression
 - Blocked for undercut
 - Even thickness for impression
- 437) Pt. blow in the anterior maxilla has lefort 1 where to put peak of row deimpacted forceps in :**
- Zygomatic process
 - Canine eminence
 - Maxillary tuberosity
 - Hard palate along nasal floor ***
- 438) (T) or (F) :**
- Endo ttt fracture non endo tooth
 - Cantilever non endo ttt better than cantilever endo ttt
 - Both are true ***

439) (T) or (F) :

- a. Successful ttt not depend attitude perception
- b. Successful ttt not depend attitude perception
- c. Both are false ***

440) 6 years old , all his primary molar need filling , multiple caries the ttt is :

- A. Amalgam
- B. Composite
- C. Stainless steel crown
- D. Glass ionomer ***

441) Class 4 restoration reach to the cementum :

- a. G.I ***

442) Sinus tracing by gutta perch :

- a. Chronic periodontitis ***

443) To suggest breathing in non conscious pt. :

- a. Call CPR ***

444) Amalgam cavo-surface angle :

- a. 90° ***

445) Contact of which tooth is in incisal or Occlusal third :

- a. Max. canine
- b. Mand. Incisor ***
- c. Molar

446) Apical periodontal cyst :

- a. Epithelial rest of malaise***

447) Most important avulsed tooth :

- a. Time***

448) Most palate retentive :

- a. U shape ***
- b. V shape
- c. Knife edge

- 449) All are property gutta percha except :**
- R.L***
 - Compatible
- 450) First molar RCT disto-mesial small cones the restoration is :**
- Cast gold crown***
- 451) 7½ old child he has discoloration in upper right central (trauma before one year) the management is :**
- Apexcification***
- 452) Hemidesmosome Basel cell epith. attached to :**
- Lamina Lucida
 - Lamina densa
 - Lamina propria ***
- 453) Topical fluoride applied :**
- 3 months
 - 6 months***
- 454) Suture resorbable for inner. Surface of face resob. in 4 months:**
- Catgut***
 - Plain gut
 - Propylene
- 455) Down syndrom pt, has :**
- Fissured tongue and protrusive***
 - High caries index
- 456) All are for retention of maxilla except :**
- Tongue mobility***
- 457) Line on the buccal of permanent teeth :**
- Non ebner
 - Stria zoster
- 458) On buccal mucosa when scrapped Erythematous :**
- Erythema
 - Candida***
 - Lichen plannus
- 459) Composite lighter :**
- Shade selection prior to isolation***

460) Equipment aid all of following for light cure except :

- a. Voltage line
- b. Infection barriers
- c. Resin contamination
- d. Pulp degeneration***

461) Short margin crown due to :

- a. Metal to hot
- b. Bur on temperature high
- c. Sprue short wide

462) Porcelain veneer :

- a. Light cure
- b. Resin modified glass ionomer

463) For retention of cement on crown tooth preparation was done not good :

- a. Remove extra inter proximal cement by spatula***

464) Onlay gold maximum :

- a. 1.5mm***
- b. 1 mm
- c. 2mm
- d. 2.5mm

465) Para function habit bruxism (incisal Occlusal) :

- a. Attrition ***
- b. Abrasion
- c. Erosion
- d. Abfarftion

466) For decrease periodontal problem most effective way in addition to antiseptic solution

- a. Dental health education***
- b. Through and remove of plaque

467) In indication of parameter of periodontal :

- a. Attachment loss
- b. Bleeding***

468) Retainer :

- a. Cobalt chromium***
- b. Nickel chromium

- 469) All are wrong except :**
a. No clearing and shaping until working length determined
- 470) Distal extension impression what impression tissue at rest :**
a. Plaster of Paris
b. Modified plaster
c. Zn oxide eugenol***
- 471) Caries in upper 6 ,6 and lower 6 ,6 & suspect caries in upper 7,7 and lower 7,7 what is the ttt :**
a. Restoration for all 6 and pit fissure sealant for all 7***
- 472) Why alloplast do demineralization of bone with cold :**
a. Hydro choleric material ***
- 473) Snyder test mean what for dental caries :**
a. Amount of acid producing microorganism
- 474) Pt. 45y old how to do gingival cleaning :**
a. Gingival embrasure ???
- 475) Loss of periodontal inter Radicular :**
a. Furcation ***
b. Periodontal
- 476) What mean dental primer function in open :**
a. Remove smear layer (penetrate into collagen framework and copolymerize with the resin ***
- 477) Maxillo mandibular fixation the steel wire size of gauge:**
a. 6 inch or feet 26 gauge ***
- 478) Incidence of disease is 350 in 1000 population , the mean time is in 7y (prevail) is :**
a. (35)
b. (350)
c. (50)
d. (24)***
- 479) Post easily fracture in root :**
a. Threaded post***
- 480) Relation bet. Apex and base when doing flap :**
a. Lateral wall diverge from apex to base***

- 481) Best way to detect incipient caries is :**
A. Digital fiber optic ***
B. Visible light
C. Ultraviolet light
- 482) A tooth in x-ray shows 1quarter of its root form so when the tooth emerge in the oral cavity :**
a. $\frac{3}{4}$ of its root will be formed***
- 483) Balanced occlusion in natural teeth on both side mater position of mand. :**
a. False false***
- 484) Dull & crumbly amalgam due to :**
A. Over trituration
B. Under trituration ***
- 485) Emergency endo except :**
a. Establish diagnosis***
- 486) Emergency endo after x-ray :**
a. start endo
b. See vitality ***
- 487) ER endodontic treatment should not be established by :**
A. Check restorability
B. Establish diagnosis ***
C. Relive pain with analgesic
- 488) You did root canal ttt for pt. still persistent pain as emergency ttt what to do :**
a. Give him analgesic***
- 489) Tooth number 15 has been stained by tetracycline removed by :**
a. Micro abrasion***
- 490) Posterior $\frac{1}{3}$ of palatin innervated by :**
a. Posterior palatin nerve***
- 491) Extra oral INF alveolar injection pt. trismus inject lateral :**
a. Upward + post***

492) Amalgam flush mean :

- a. Thin part of amalgam in on prepared tooth surface under cavity
- b. Thin part of amalgam over carving ***
- c. Thin dentin wall
- d. 90° cavo surface angle

493) 3rd incision done by :

- a. Orben knife***

494) Floride water supplementary and we want to give systemic fluoride what to ask pt. :

- a. Age ***
- b. Amount of fluoride
- c. Time of fluoride

495) Anesthesia tech. :

- a. Amount of bone***
- b. Focal anesthetic agent

496) Young pt. on examination , multiple carious white chalky , red inflamed gingiva , ↑ plaque index , pocket depth 2-4 mm , what's the periodontal diagnosis :

- A. Rampant caries
- B. Juvenile periodontitis
- C. Gingivitis
- D. High caries index ***

497) After 3 weeks from delivery of distal extension RPD unilateral a sensitivity abutment happened (sensitive to percussion) what is cause :

- a. Defective occlusion***
- b. Occlusal rest seat dentin under in exposed
- c. Sensitive dentine basing retentive

498) Amalgam alpha 2 :

- a. 13%***

499) Dentinogenic infection give AB :

- a. Diffuse rapidly progress***
- b. Localized alveolitis
- c. Localized

- 500) In order to change size of tooth by altering gingival contour by :**
- Mesio facial surface , disto facial surface apart
 - Mesio facial surface and DFS near incisally***
- 501) Spontaneous pain last 30 min :**
- Irreversible pulpitis***
- 502) Record finish line by impression cord :**
- Mech. + chemical***
- 503) 3 village :**
- Cross section***
- 504) Water supply dental unit (air water system) sterilization :**
- 20-30 sec bet. Pt. ***
- 505) Bacteria spore in sterilization :**
- Weakly put bacteria spore ***
 - Bacteria spore in accessible area
- 506) Pregnant safe period to work :**
- 2nd semester***
- 507) Pt. pregnant having chronic periodontitis :**
- P gingivalis
 - P intermediation ***
- 508) Sterilization of gutta percha by :**
- Chemical solution ***
- 509) Anesthesia want to do aspiration carpool inserted 1st followed needle simultaneous :**
- Excessive force needle***
- 510) Calculus :**
- Harbor bacteria***
- 511) Pit and fissure sealent lest have successability to caries :**
- Less than non sealed***
- 512) 2x4 appliance :**
- Intruded malalignment***

513) Anesthesia when doing restoration :

- a. No pain during dental problem ***
- b. Decrease saliva
- c. Decrease hemorrhage

514) Pedo pt. 2y old has intruded central incisor :

- a. Anterior Occlusal x-ray***
- b. 2 bite wing
- c. O.P.G
- d. 2 bite wing +2 Occlusal x-ray

515) Sialolithiasis mand. Sialometaplasia submand. Gland , best to see by x-ray exposure intensity of dental :

- a. Half***
- b. Same
- c. Double

516) Alloplast grafting (ca ph)

- a. Tris phosphate ***
- b. Iliac
- c. Ca phosphate***

517) Heat curic acrylic resin regarding heat :

- a. Heat is mandatory for polymerization***

518) TMJ degenerate pain auricular :

- a. Arthrography

519) To fabricate FPD in high pontic illusion at the same time easy to clean :

- a. Modified ridge lap***

520) The most irritant to wound healing :

- A. infection ***
- B. excessive bleeding
- C. torn edge

521) Epithelial rest of cell :

- a. Entrapment epithelial cell cause granuloma ***

522) H- files has more cutting efficiency compared to k-files due to :

- A. More negative rake angle
- B. More positive rake angle ***
- C. More cutting tip

523) 1ry restoration of amalgam restoration by :

- a. Converge occlusaly***

524) Reline :

- a. To compensate for bone loss ***

525) Decrease internal stress :

- a. Increase placement stress breaker***
- b. Increase placement stiff breaker liner

526) Pier abutment means :

- a. Edentulous spaces Mesial and distal ***

527) Ideal impression material characteristic :

- a. Short working time , long setting time***

528) Metal post not indicated for using it :

- a. 25 % lost tooth structure***

529) In order to good RCT :

- a. 1 to 2 mm short than W. L***

530) Pedo. Patient with sever toothache, prevent him to sleep , upon examination large caries in lower permanent molar . treatment is :

- A. Pulpectomy ***
- B. Ca(OH)₂ Pulpotomy
- C. Direct pulp capping

531) Dental implant bone damage :

- a. At 45→iminute ***

532) Sinus in :

- a. Degenerative pulp***

533) Vestibuloplasty which tech. pt. having maxillary complete denture (high renal attachment) shallow vestibule good labiolingual vestibule :

- a. Clark- tech.
- b. (Kazangachi- tech.)
- c. Transposition- tech.
- d. Obweg- tech. ***

- 534) Technical assault mean , after doing dental ttt pt. complain technical assault :**
- Hemorrhage trauma during dental ttt
 - Not doing proper ttt which pt. need it
 - Not doing any inform consent ***
 - Psychological , physical assault like – verbal
- 535) Evidence based research scientific paper identifying failure of material not important when using material , is one of important conventional due to increase durability esthetic :**
- 2 statement T
 - 2 statement F
 - 1st F 2nd T***
- 536) RCT contra indicated in all except :**
- Tooth with periodontal lesion***
- 537) MOD amalgam restoration , the cement used under it should have :**
- ↑Modulus of elasticity***
- 538) 33 y with severe pain stimulate by hot drinks & last for 10 sec. after remove stim. Pt. have :**
- Irreversible pulpitis ***
- 539) Pt. have class 2 bone defect in order to have regeneration we fill the defect by which type of bone :**
- Cancellous bone***
- 540) Fluoride toxicity for adult 60kg or (10 – 5 g) :**
- 32-64 mg/kg ***
- 541) Failure of amalgam is due to :**
- Brittleness, high modulus of elasticity
 - Brittleness, corrosion , low tensile of strength ***
 - Rigidity ,corrosion, low compressive strength
 - Rigidity , high tensile strength
- 542) Oral surgeon wants to check histopathology of a lesion on the lateral of the tongue. the best way to hold the tongue is :**
- Minnesota retractor
 - Wider tongue retractor
 - Hold the tip of the tongue by towel holder ***
 - Retract with mouth mirror

- 543) The device of frequent brush in order to prevent accumulation of calculus by :**
- Prevents break matrix of plaque***
- 544) Initial reaction is acid base in which material :**
- G.I***
- 545) Which material release florid which uptake by enamel and cementum :**
- G.I***
- 546) Surgeon wanted to sterilize a tray made from heat resistance plastic tray how to disinfect according to infection control guide :**
- Dry heat oven**
 - Moist heat **
 - 2% glutaraldehyde
 - Chemical
- 547) Histopathology of nicotinic stomatitis :**
- Acanthosis & hyperkeratinization of epith.***
- 548) (T) or (F) The outcome of non surgical endo. Re tt. Without preiapical involvement is better than with preiapical involvement :**
- (T) & (T)
- 549) Sharp fast pain :**
- Sensitivity***
- 550) Which is true regard to central incisor :**
- The cingulum is in the middle $\frac{1}{3}$ palatally (F)
 - Mesio distal wider than occluso gingival (F)
 - Mesial edge is rounded than distal edge (F)
 - (T)
- 551) It is necessary in perp. For all porcelain to remove all sharp angle in order to reduce stress concentration. It is necessary in FPD prep. To remove sharp angle :**
- T,T
 - F,F
 - T,F***
 - F,T

552) Pt. 30y old has class 2 miller recession in upper Rt. Canine what is the type of flap used in root coverage , not the tech. used in R.C is low

- a. Full thickness flap under split flap
- b. Full thickness under full thickness or C.T
- c. Connective tissue under full thickness
- d. Connective tissue under split ***

553) Lingual bar used for :

- a. Better esthetic ***

554) Most effective way for water control :

- a. Rubber dam***

555) Bacteria in community communicate with other bacteria with process called :

- a. Quorum sensing***

556) When tooth erupt until attached to which part of epith. :

- A. Lamina Dura
- B. Lucida
- C. Lamina densa ***

557) Rowe's disimpaction forceps used in lefort 1 where this forceps attached :

- a. Hard palate of base of nose***

558) Pt. has ulcer in edentulous area , xanthomatosis diabetes, x-ray show air float teeth what's diagnosis :

- a. chediak higashi syndrome
- b. Hard Christian syndrom

559) Pt. had bone dis. He is doing orth. ttt the teeth is not move with orth. because pt. taking medication what is the medication:

- a. Vit D ***
- b. Misoprestor

560) Chronic suppurative apical periodontitis what is mean :

- a. Acute inflammatory cell lining drain sinus tract***
- b. Lesion drain in sinus tract

561) Eruption hematoma (over tooth) before few weeks from eruption the ttt. is :

- a. No ttt***

562) Infection in root canal system :

- a. Aerobic
- b. Non aerobic
- c. Aerobic and non aerobic***

563) Composite class 2 , proximal weak use :

- a. Wedge
- b. Circumferential matrix with wedge ***
- c. Segmental matrix wedge

564) Non active caries :

- a. Soft and cheesy ***
- b. Hard and dark
- c. Pain on excavation
- d. Pigmentation dark

565) Prefabricated post all except :

- a. Stainless steel
- b. Titanium
- c. Acrylic unfilled resin
- d. Acrylic resin ***

566) FPD separated porcelain from metal when :

- a. Ectopic force in junction bet. Porcelain and metal ***

567) FPD mechanical failure when :

- a. Long span with cantilever FPD ***

568) Best type of porcelain fusing temp :

- a. High fused porcelain ***
- b. Medium fused porcelain
- c. High and medium fused porcelain

569) Customized tray best in final impression why :

- a. Can used in alginate impression
- b. Good in taking impression with details and can adapt during taking impression ***
- c. Semisolid to be easily removed

570) Pedo. Pt. had toothache at night he had badly decayed permanent molar :

- a. Direct pulp capping
- b. Indirect pulp capping
- c. Pulpotomy
- d. Pulpectomy ***

- 571) 5 y old did extraction , after few days came with fever , sore throat ,cervical lymphadenopathy , pain , bleeding ,investigation show anemia ,thrombocytopenia WBC low :**
- Acute lymphoblastic leukemia ***
 - Acute myeloanemia
 - Chronic myeloanemia
- 572) Coronal bone bet. Which bone :**
- Frontal and temporal bone***
- 573) Most effective hemostat of most power full :**
- Gelatin sponge
 - Bone wax
 - Oxide cellulose ***
- 574) Adult pt. has distal caries , anterior abraded incisal edge :**
- Full crown
 - All ceramic
 - All veneer
 - Partial veneer crown ***
- 575) Long span distal caries 1st molar , the 2nd molar toward depth of caries of 1st molar :**
- Inter coronal restoration 1st molar
 - Restoration 1st molar enamel of last 2nd molar ***
 - Provisional crown
- 576) In composite class 2 internal stress :**
- Incremental place which stress break liner **
 - Incremental place which stiff break liner **
- 577) Supplementary injection in endo. :**
- Intra Pulpal
 - Intra ligament
 - Palatal and lingual
 - All ***
- 578) 3 walls defect tilled which osseous coagulum means :**
- Cancellous which blood fill**
 - Cortical mix blood fill**
- 579) Best allograft at used :**
- CDFBA Cancellous dried frozen bone allograft***

580) Surgeon want to do reduce mentoplastiy he should avoid which nerve :

- a. Mental nerve***

581) When you apply pressure to palatine foramen pt. feel irritant due to:

- a. Posterior palatine nerve ***

582) What is the un accurate impression material :

- a. Alginate***

583) When effective time, what is the conc. Of ethanol alcohol to be affect on bacteria "

- a. 60
- b. 50
- c. 70***
- d. 80 or 90

584) All of these material are used in post and core except :

- a. Gold
- b. St.st.
- c. Resin ***

585) 7 y old with trauma in his central incisor , the dr. wanted to Apexification in single visit :

- a. MTA***

586) Best point to support rubber dam :

- a. 2 point 2 buccal and 2 lingual ***

587) Chose of L.A depend on :

- a. Type of L.A
- b. (Strength) of bone***

588) Long bone formed by endo (chondral)ossification(whant) and let bone formation :

- a. (T)***

589) Ca(OH)₂ :

- a. Antimicrobial action***

590) One of these muscles Inserted to articular disc :

- a. Lateral pterygoid muscles ***

591) Sq. cell car. Start 1st as :

- a. Red plaque***

592) Shrinkage of porcelain of FPD is :

- a. 1-5 %***

593) Most stable tooth colored material :

- a. Porcelain***

594) Which one increase with hairy tongue :

- a. Filiform papillae***

595) Face bow is used to :

- a. Mount the maxillary cast***

596) The most important factor in porcelain while doing FPD :

- a. Compressive strength ***
- b. Tensile strength
- c. Modular elasticity
- d. Hardness

597) Material used in bleaching as walking & min hydrogen peroxide in which barium sulphate :

- A. Hydrogen peroxide mix with barium sulfat
- B. Superoxol with sodium perborate ***
- C. H₂O₂ with sodium perborate

598) Apexification :

- a. (Barrier) at apical part***

599) What are the autoclave used in dental office :

- a. Autoclave system A
- b. Autoclave system B***

600) Amount of zinc oxide in G.P is :

- a. 70% GP & 30% zinc**
- b. 70 % zinc oxide & 20 % GP **

601) Mand. Fracture , plate fixation 2mm what's the size of drill :

- a. 1.5 ***

602) Dental material fixed by :

- a. Light cured resin cement***

603) Purpose of porcelain condensate :

- a. To remove excess H₂O so ↓ firing shrinkage
- b. To ↓ porosity***
- c. To adapt the paste in the req. form

604) Noble and non noble : note

- a. High noble alloy (gold – platinum –palladium) (60% precious metal)
- b. Noble alloy (semi –precious metal = 25% of precious metal)
- c. Non-noble alloy (nickel – chromium – gold) non precious metal

605) Pt. sensitive to penicillin what is the AB :

- a. Clindamycin 500 mg***

606) The fitting surface of bridge :

- a. Leave it as it is suggested to cleaned***

607) Moon face appear in all except :

- a. Zygomatic complex fracture***

608) Major artery supply the mandible :

- a. Lingual artery ***

609) Threaded post fracture how to remove :

- a. Ultrasonic
- b. Post remove***

610) Die is done to :

- A. Allow for better waxing ***
- B. Adjust the errors in preparation
- C. Make investment easier
- D. Adjust correct finish line

611) White spot in maxillary incisor , history of trauma :

- a. Turner tooth***

612) All posterior teeth in contact , and all anterior teeth is not contact :

- a. Centric occlusion
- b. Balanced occlusion
- c. Protrusive occlusion
- d. Lateral extrusion

613) Halterman appliance for:

- a. Oral habit
- b. Cross bite
- c. For correct improper eruption molar ***

614) What attrition to natural teeth :

- a. All porcelain***

615) Criminal vulnerability :

- a. When the doctor work without lenience***

616) ↑ retention of full crown short molar :

- a. Vertical groove***

617) Which temp. can cause damage to bone cells' :

- a. 46° for 1 min. ***

618) Minor which is independent of the parents which can sign consent form independently :

- a. prudent
- b. Non prudent
- c. Speedo minor***

619) Metal not used in complete denture due to :

- a. Inability to reline ***

620) Acid etching for pit and fusser sealent is done to :

- a. More surface area + more retention surface***

621) Optic foramen :

- a. Sphenoid***

622) How to accelerate setting time in dental stone :

- a. ↑Water
- b. Cold water
- c. ↑Mixing time ***
- d. Vacuum mixer

623) Tooth with questionable Pulpal & periodontal diagnosis , 2 cusps are , best ttt. :

- a. Composite
- b. Amalgam
- c. Crown
- d. Extraction and fixed ***

624) Sinus tract indicate :

- a. Chronic suppurative periodontitis or Degenerative pulp***

625) Dry socket :

- a. 3-4 day***

626) Impression material do not used in fixed due to inaccurate :

- a. Agar agar ***

627) Impression material with bad Oder and taste :

- a. Poly sulphide***

628) Pt. with severe pain , normal finding , history bridge cementation few days ago :

- a. Acute apical periodontitis***

629) Endodontic sealer is used to :

- A. Fill the voids ***

630) Giving reward to the pedo pt. is called :

- a. +ve reinforcement***

631) Best material for RCT for 1ry teeth is :

- a. Zinc oxide eugenol***

632) Cells that give apical periodontal cyst are epithelial root cell of hertwig's sheath:

- a. rest of malassez***

633) Most complain after denture insertion by 1 day :

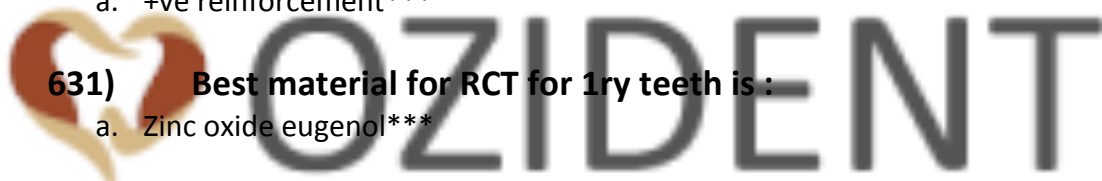- a. Extended flange***

634) Using instrument that produce elliptical motion :

- A. Sonic
- B. Ultrasonic
- C. Magneto station ***

635) What is non resorbable suture :

- A. Silk***



636) Patient with tetracycline staining (very mild brown – yellowish) the treatment is :

- A. Microabrasion
- B. Bleaching***
- C. Composite veneer

637) In Ceramometal all except :

- A. Irregular sharp finish line ***

638) Accidentally etched enamel will reach complete remineralization in :

- A. Few days of exposure to oral fluids. **
- B. 2 weeks
- C. Few months**
- D. Never achieve complete remineralization

639) During eruption of lower mandibular molar , there is a specula of hard tissue in the central fossa when the tooth is erupting , this is called :

- A. Ectopic eruption
- B. Hematoma
- C. Eruption sequestering***
- D. Eruption cyst

640) All of the following are endo irrigation except :

- A. Na cl
- B. RC prep. (EDTA chelating Agent) ***
- C. Saline
- D. Hydrogen peroxide

641) (Why you do balanced occlusion in central occlusion) :

- A. Easy to fabricate
- B. Comfortable to the patient
- C. Increase stability of the denture ***
- D. Decrease ridge resorption

642) Fluctuant abscess , what is the blade used for start incision :

- A. 11 ***
- B. 12
- C. 15
- D. 16

643) The Space between upper primary lateral and canine called:

- A. Primate space ***
- B. Freeway space
- C. Leeway space

644) Endo failure is due to difficult removal of which organism

- A. staphylococcus aureus
- B. Streptococcus mutant
- C. enterococcus faecalis + actinomyces ***

645) In Removable denture placement for primary incisor we use :

- A. Punch smallest hole***
- B. Medium hole

646) Pain to percussion :

- A. Inflammation of the preiapical area ***

647) Over reduction preparation of the metal crown margin will cause all except :

- A. Will increase retention similar to sandblasting ***
- B. Effect retention
- C. May cause open margin

648) Most common complaint after denture insertion is :

- A. Over extended causing laceration ***
- B. Rough
- C. Difficult to adapt with

649) When to restore enamel caries :

- A. ½ enamel
- B. Pass DEJ ***
- C. Spread laterally in dentine

650) Lethal dose of fluoride for 60kg adult is :

- A. 50 – 60 mg/k
- B. 30 – 60 mg /k ***
- C. 70 – 80 mg /k

651) Marginal ridge integrity of the restoration should rest on :

- A. Long enamel rods and dentine ****
- B. Long enamel rods and short rods
- C. Short enamel rods

652) Type of inter dental clean device depend on :

- a. Age of pt.
- b. Type of pathology
- c. Type of gingival imbreassion***

653) To plane the facial and the lingual wall of enamel , which enamel will use :

- A. Enamel hatchet ****
- B. Gingival trimmer
- C. Chesil
- D. Plane line angle

654) Analgesia is :

- A. Absence of pain to all sensation.
- B. Absence of pain that is normally painful ***
- C. Diminish sensitivity to all sensation

655) Retrieve of old gutta percha from canal by :

- A. Chemical
- B. Mechanical
- C. Thermal
- D. Combined heat and chemical solvent ***

656) Amalgam and retrieve pin should be inserted in :

- A. Enamel
- B. Dentine ***
- C. EDJ

657) The material used for fabrication of mouth guard:

- A. Polyether ***
- B. Polyvinyl acetate

658) The relation between teeth in pedo. Patient is :

- A. Terminal flash
- B. End to end
- C. Class I occlusion
- D. Class II occlusion ***

659) Patient came complaining from bad mouth odor and gingival bleeding :

- A. NAUG ***

660) False negative vital test due to :

- A. History of trauma ***
- B. Uncooperative patient

661) Balance occlusion is :

- A. Favorite contact between upper and lower teeth in centric occlusion and extenceric occlusion***
- B. Favorite contact between upper and lower teeth in centric occlusion only
- C. Favorite contact between upper and lower teeth in extenceric occlusion only

662) Best enamel :

- A. Long enamel rods supported by short enamel rods and they are supported by dentin. ***
- B. Long enamel rods supported by dentin
- C. Long enamel rods supported by restoration

663) The nerve supply for lower canine and incisors are :

- A. Inferior Alveolar nerve ***
- B. Long buccal nerve
- C. Lingual nerve

664) To avoid crown fracture in PFM:

- A. Avoid sharp projection in the underlining metal ***
- B. Contact be on porcelain

665) Fusing of procaine need :

- A. Low temperature
- B. High temperature ***
- C. Mixed temperature.

666) Maryland bridge use when(indication) :

- A. Retain lower anterior ***
- B. To replace more than 1 tooth
- C. Short lingual sulcus

667) Maryland bridge indicate :

- A. 2 missing
- B. Young patient ***
- C. When need translucency
- D. When abutment is extensively restored

668) Cantilever bridge use to replace :

- A. Lower lateral
- B. Lower molar
- C. Upper lateral ***
- D. Upper canine

669) To select an abutment we look for except :

- A. Mobility
- B. Crown length
- C. Crown / root ratio
- D. No. of roots and their surface
- E. History of ortho. ***

670) Impression material that can be poured more than once:

- A. Polyether
- B. Additional silicon***
- C. Polysulfide

671) Most accurate impression material :

- A. Alginate
- B. Additional silicon ***
- C. Polyether

672) To decrease composite shrinkage :

- A. Put composite in increment layer ***
- B. Low starting – curing light is used

673) Most retentive cement :

- A. Polysulfide
- B. Polyether***

674) Patient came to your clinic with left eyelid are closed , left side of the face is semi paralyzed, the left corner of the mouth can't smile accurately and elevate eyebrow . what cranial nerve is affected :

- A. Facial nerve ***
- B. Trochlear nerve.
- C. Trigeminal nerve

675) Best property of cement under amalgam rest :

- A. High tensile strength
- B. Low tensile strength
- C. Tensile strength not important ***

676) The important property of cement under amalgam :

- A. High modulus of elasticity ***
- B. Low modulus of elasticity
- C. modulus of elasticity not important
- D. High modulus of elasticity and low tensile strength

677) Best property of cement under restoration :

- A. Compressive strength
- B. Rigidity ***

678) Incipient caries :

- A. Enamel is not affected by caries
- B. Enamel is high surface porous.
- C. Not irritant to pulp ***

679) Tooth colored restoration transfer from betty to solid by :

- A. Acid base reaction
- B. Polymerization reaction ***
- C. Participant reaction
- D. All of above

680) Enamel caries proximally :

- A. Should be restored immediately ***
- B. Should be restored when reach DEJ
- C. Should be restored when reach DEJ and wide spread start.

681) Rampant caries in child :

- A. Lower incisor
- B. Upper incisor***
- C. Lower molar

682) Fluoride application should be done :

- A. Every 1 year
- B. Every 3 months
- C. Every 6 mouths ***
- D. Every 18 months

683) RPD preferred than fixed in :

- A. Patient can't maintain good oral hygiene
- B. Bilateral missing teeth ****

684) Difference between abscess and cellulites is :

- A. Cellulites is more diffuse than abscess without pus***
- B. Abscess is more diffuse than cellulites without pus.
- C. All like each other need medication and drainage

685) Pin using :

- A. Only in enamel
- B. Only in dentine ***
- C. In enamel and dentine
- D. Any of the above

686) Local factors as a contraindication for extraction :

- A. Radio necrosis
- B. Tumor at the site of extraction ***
- C. Tooth at Fracture line

687) Caries is reversible process by remineralization in enamel except if it extend to protein :

- A. 1st statement are true & 2nd statement are false
- B. 1st statement are false & 2nd statement are true
- C. Both true ***
- D. Both false

688) Least corrosion amalgam are :

- A. γ_1
- B. γ_2 ***

689) White lines after composite restoration placed immediately due to :

- A. Polymerization shrinkage
- B. Improper finishing tech. ***

690) 9 y old patients had trauma to upper central incisor, fractured tooth with minute pulp exposure. the treatment is :

- A. RCT
- B. Pulpotomy ***
- C. Pulp capping

691) Ca(OH)₂ used at the canal in RCT between visit because :

- A. Anti- microbial ***
- B. Temporary seal the canal

692) Specific plaque hypothesis :

- A. Plaque is pathogenic when disease symptom appear
- B. Remove of all cryogenic plaque is important
- C. All plaque is pathogenic
- D. A & B ***

693) Patient came to your clinic at early morning, can't sleep since 4 o'clock AM, there is a severe pain on his tooth Diagnosis :

- A. Irreversible pulpitis***
- B. Reversible pulpitis

694) Patient came with failure RCT. best treatment :

- A. Surgical endo
- B. Antibiotic
- C. RE Endo. ***

695) The success of measuring for the using of Ca(OH)₂ in pulp capping tech:

- A. No symptom pulpitis ***
- B. Creation of barrier under Ca(OH)₂ on exposed pulp

696) Radicular cyst with :

- A. Vital pulp
- B. Non- vital pulp ***

697) During access cavity , it is important to concentrate on :

- A. Remove caries before access opening ***
- B. Take diagnosis radio graphically
- C. Use rubber dam

698) Stress force absorbed until fracture occur called :

- A. Rigidity
- B. Modulus of elasticity
- C. Compressive strength ***

699) Thin alveolar opposed natural teeth best choice of the teeth :

- A. 0 ° ***
- B. 20 °
- C. 33 °
- D. 15 °

700) Increasing in incisal guidance it mean change in:

- A. Vertical dimension of occlusion ***
- B. Overlap

701) Difference between centric occlusion and centric reaction :

- A. 0 mm
- B. 3 mm ***
- C. 6 mm

702) 1st step in planning of removable prosthesis :

- A. Guidance plane ***

703) For good planning :

- A. Study cast ***
- B. Master cast

704) Syneresis is property of :

- A. Agar
- B. Alginate ***
- C. Compared

705) Ideal location for person making x-ray is :

- A. 25 ° - 30 °
- B. 50° - 90 °
- C. 90 ° - 135 ° ***

706) Parotid gland include :

- A. Facial nerve ***
- B. Lingual nerve
- C. Facial artery

707) Lingual nerve branch of :

- A. Facial nerve
- B. Mandibular nerve ***

708) GI restoration :

- A. susceptible to hydration over life time
- B. susceptible to dehydration over life time with free monomer ***
- C. All of above
- D. B & C

709) Acid base reaction:

- A. GI ***
- B. Modified resin GI
- C. Composite resin

710) The least indication for FPD is :

- A. Patients demands ***

711) Tip of the tongue drain at :

- A. Submandibular L.N
- B. Submental L.N***
- C. Sublingual L.N

712) Occlusal 2/3 of cementum contain :

- A. A cellular & vital fiber & vital cementum ***
- B. A cellular & non vital fiber & non vital cementum
- C. Cellular and mixed fiber

713) Cavity test :

- A. Consider non aggressive
- B. Common diagnostic test
- C. To see necrosis. ***

714) Luting cement under fixed prosthodontics :

- A. 2 – 5 micron
- B. 25 – 40 microns ***
- C. 0.5 – 1 microns
- D. 1 – 2 microns

715) Mandibular fracture :

- A. Nasal bleeding
- B. Malocclusion ***
- C. Infraorbital bleeding

716) Most common cause of coma in dental clinic :

- A. Diabetes
- B. Vasovagal shock ***
- C. Hypertension

717) Local anesthesia of 2% xylocain with 1/100000 epinephrine :

- A. 0.02 mg
- B. 0.2 mg
- C. 1.8 mg
- D. 36 mg ***

718) Angular cheilitis , most common :

- A. Low vertical dimension of wearing prosthetic patient ***

719) All the following with Dentinogenesis imperfect except :

- B. Fractured enamel
- C. Fractured long bone
- D. Multiple supernumerary teeth ***
- E. Blue sclera

720) Rough wire :

- A. Decrease stress on abutment

721) Flexibility of retentive arm affected by all except :

- B. Length of retentive arm
- C. Cross section
- D. Type of alloy
- E. Location of high contour ***

722) Class V can be applied composite in what case :

- A. When margin in enamel only ***

723) Fluoride in dental office not cause fluorosis because :

- A. Very little amount of fluoride
- B. Tooth already calcified ***
- C. Dentist put protector
- D. Saliva wash the fluoride

724) Pellicle :

- A. Soft organic protein adhere to tooth structure***

725) Abutment for FPD is more reliable to fracture if RCT

Cantilever suspended on abutment :

- A. Both statement are true ***
- B. Both statement are false

726) Diabetes mellitus infected after Dental treatment due to impaired of :

- A. Lymphocytes
- B. Macrophages ***

727) Cells responsible for production of antibodies :

- A. T – lymphocytes
- B. B – lymphocytes ***
- C. Plasma cell
- D. Macrophage

728) Pit and fissure :

- A. Newly erupted
- B. Deep pit and fissure
- C. A & B ***

729) Giving alcohol sufficient time, the degree of ethanol alcohol disinfection :

- A. 70 %***

730) Pedo pt. with physical retardation & negative behavior the inappropriate thing to do is :

- A. Send him home***
- B. Use

731) Pedo pt. with extremely -ve behavior to restrain the extremity :

- A. Use mouth prop
- B. Belt
- C. papoose board ***

732) During anesthesia what's true :

- A. The needle should be inserted before cartridge
- B. The needle cap is inserted before the stopper ***
- C. Excessive force should be applied to allow insertion of the cartridge into the harpoon

733) High copper amalgam is repeated if :

- A. Marginal detaching is less than 0.5 mm
- B. Marginal leakage with food impaction ***
- C. Unaesthetic discoloration

734) Pt. with sialolithiasis we want to take x-ray with ordinary film in the stone we should :

- A. Take x-ray in the same way as usual
- B. Increase the intensity of x-ray
- C. Decrease the intensity of x-ray ***

735) During endodontic surgery the irrigation used is :

- A. Saline ***
- B. EDTA
- C. Na Cl

736) Retrograde filling is indicated in what condition :

- A. Max. central incisor with good filling with 9 mm radiolucency ***
- B. Max. premolar with post & core & buccal root with 4 mm short filling & RL at the apex but the palatal root with good filling
- C. Max. 1st molar with MBR & DBR short filling & palatal root with fracture instrument

737) What's true about the mandibular canal :

- A. Above the Occlusal plane in children
- B. Below occ. Plane in children ***
- C. Below occ. Plane in adult
- D. At the occ. Plane in adult

738) Wall defect in perio what's the best graft to treat this defect :

- A. Cortical freeze dried bone allograft
- B. Cancellous freeze dried bone allograft ***

739) To increase the retention of full crown for a short molar :

- A. Use zinc phosphate
- B. Retentive vertical groove ***
- C. Shoulder finish line

740) During perio surg. For the pt. with chronic periodontitis we found carter how is it removed:

- A. Osteotomy ***
- B. Osteoplasty
- C. Gingivectomy

741) X-ray of parotid gland if pt. has iodine sensitivity :

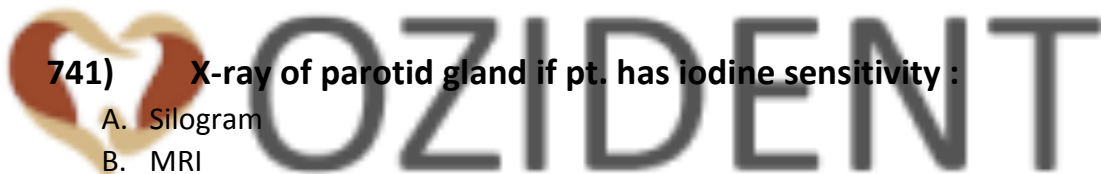- A. Silogram
- B. MRI
- C. Computed tomography (C.T) ***

742) The degree of taper of crown prep. :

- A. 3-5
- B. 15
- C. 6***

743) Pt. infected by anthrax after examination doctor should disinfect with :

- A. 12 % chlorohixiden
- B. Antibacterial hand scrub ***
- C. Non antimicrobial soap



744) Giving sufficient time the degree of alcohol disinfection :

- A. 50 %
- B. 60 %
- C. 70 % ***
- D. 80 %

745) The pedo pt. behavior after 1st visit is affected by which environmental factor :

- A. Behavior shaping
- B. At home
- C. The doctor & nurse showing great care ***

746) Submandibular space infection is drained :

- A. Intraorally at mylohyoid
- B. Extra orally below the inferior border ***

747) Which of the following is contraindicated to lingual bar :

- A. Deep lingual sulcus
- B. Shallow ling. Sulcus ***
- C. Crowding in lower anterior
- D. Spacing + diastema in lower ant.

748) Amalgam flash is :

- A. Thin part of amalgam in unprepared tooth surface due to under covering
- B. 90 ° cavosurface angle or beveling 90 ° ***
- C. Thin dentin wall

749) Regarding amalgam trituration :

- A. Should wait 2-3 minute before starting condensation to allow mercury vaporization
- B. The mix should be placed immediately with good condensation & adaptation ***
- C. Should be condensed vertically only not laterally

750) Odontogenic cyst :

- A. Rarely malignant ***
- B. Form from the tooth structure
- C. Characteristic x-ray
- D. Unique biological difference during development

751) Best instrument to plane gingival in class 2 is :

- A. Gingival marginal trimer ***
- B. Hatchet
- C. Chisel

752) Large cyst with questionable vitality, how to check vitality:

- A. Cavity test
- B. Vitality test
- C. Cavity test under local anesthesia ***
- D. Percussion is the best

753) least corrosion resistance phase of amalgam is :

- A. Ag-Hg Gama 1
- B. Cu-Ag
- C. Sn-Hg Gama 2***

754) Pt. allergic to both amide + ester , GA can't be done , absolute need of L.A , we use :

- A. 1 % hydro chloramine
- B. 4 % nitrous oxide ***
- C. Benzocaine

755) Pt. with pain in lower mandibular molar , he has osteoporosis , the dentist should expect the following in OPG :

- A. Cotton wool appearance
- B. Orange peel appearance
- C. Root may not be apparent due to ↑ bone density ***
- D. Thin cortical plates

756) Pt. with severe gingival redness & hyperplasia , using local medication for nose, histopathology , eosinophils + antibodies , low plaque index :

- A. Scarlet fever
- B. Granulomatosis
- C. Rhinorrhea ***

757) Pedo pt. enjoy dental ttt, laughing, good relation with dentist, classification by franked is rating:

- A. Negative refuse treat / extreme negative behavior
- B. Negative relaxant to accept treat slight negative
- C. Positive accept treat but bad expert * uncooperative
- D. Positive definitive posit look forward prevent case ***

758) Universal sign of laryngeal obstruction :

- A. Mydriasis
- B. Tachycardia
- C. Sweating
- D. Strider ***

759) IAN is branch of :

- A. Undivided trunk of mandibular N.
- B. Anterior division of mandibular N.
- C. Posterior division of mandibular N. ***
- D. Post. Superior

760) Suspect fracture of angle of mandible , after blow to right side , best x-ray :

- A. Oblique lateral 30 ° mand. ***
- B. OPG
- C. Submentovertex
- D. Reverse town

761) The common goal for periodontal flap is :

- A. Remove granulation tissue
- B. Access to diseased root surface ***
- C. Adjust mucogingival prep.
- D. All of the above

762) Pedo pt. , gray teeth , narrow at apex , easily detached enamel probing (under pressure) :

- A. Amelogenesis
- B. Dentinogenesis ***

763) Retention of functional cusp for gold onlay :

- a. 0.5-1 mm
- b. 1.5 mm***
- c. 2mm

764) Florid toxicity dose is 5 mg/kg :

- a. 5-10 m***

765) Teeth with fallen sealant hassusceptibility to cement than teeth without sealants :

- a. Same
- b. Less***
- c. More

766) Post preparation leave of gutta percha :

- a. 5 mm***

767) Post should be inserted without pressure :

- a. Retentive***

768) Retention of veneer depend on :

- a. Mechanical
- b. Micromechanical ***
- c. Chemical

769) Pt. with Draining sinus tract the pulp is :

- a. Vital
- b. Necrotic ***

770) The dr. suspect hypophosphatasia , which of the following lab finding will assure the diagnosis :

- a. ↑ alkaline phosphatase in sever
- b. ↓ acid phosphatase in sever
- c. ↓ calcium level in sever
- d. ↑ urinary phosphoethar amine ***

771) RCT done in central incisor with abraded incisal edge , moderate Mesial and distal composite , best is :

- A. Post retained jacket crown
- B. Post retained PFM crown ***

772) All the following are advantage of PFM over porcelain except

- A. Better esthetic ***

773) How to accelerate setting of dental cement :

- A. Vacuum mixture
- B. Cold mix
- C. Increase mixing time ***
- D. Increase water

774) Permanent teeth erupt when the root is formed :

- A. $\frac{1}{4}$
- B. $\frac{1}{2}$
- C. $\frac{3}{4}$ ***
- D. All

775) 5 year old, extracted upper 1st primary molar. what is the space maintainer :

- A. Band and loop ***
- B. Crown and loop
- C. Nance appliance

776) Gingival laceration , inflammation and necrosis:

- A. NUG***

777) Type of fiber in the middle 1/3 of the tooth :

- A. Transeptal fibers
- B. Oblique fibers ***

778) After class II Furcation, periodontal management and membrane in place :

- A. Non-eugenol dressing ***
- B. Eugenol dressing
- C. Antibiotic dressing

779) Patient taking medication cause gingival hyperplasia. reason to do gingivitis :

- A. Eliminate pseudo-pocket ***

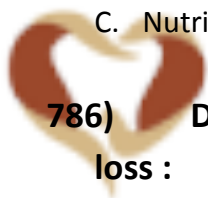780) Increase flexibility of the clasp by:

- A. Increase the length of clasp ***
- B. Decrease the length of clasp
- C. Decrease the triangular cross section
- D. Increase the diameter

781) Scissor to hold the lip during surgery:

- A. Minnesota***

- 782) Child Swallowed excessive amount of fluoride. what should parents give hem :**
- A. Milk***
- 783) Angulations of blade of scaler related to the tooth is :**
- A. 45 ° - 90 ° ***
 - B. 30 ° - 60 °
 - C. 90 – 180 °
- 784) Doctor insist the patient for treatment planed and explain to him the advantage of the treatment and not tell him the disadvantage :**
- A. Veracity ***
 - B. Autonomy
- 785) 2 years child came to your clinic complaining from white spot in all his teeth. ttt should include :**
- A. Parental counseling ***
 - B. Caries examination
 - C. Nutritional survey
- 786) Delay eruption of the teeth with insomnia and weight loss :**
- A. cleidocranial dysplasia
 - B. Hypothyroidism
 - C. Hypopituitrism ***
- 787) Radiopaque surrounding with radiolucent border in molar , premolar region :**
- A. Benign cementoplastoma ***
- 788) Intracanal medication :**
- A. Increase surface tension
 - B. Decrease surface tension ***
- 789) Advantages of Ligature wire:**
- A. Decrease stress on abutment ***



OZIDENT

790) Extensive amalgam is done:

- A. Cusps supported by dentine with enough resistance outline ***
- B. Cusps should be covered by thin layer of restoration.
- C. Undermined lost cusps.

791) Patency file :

- A. File used apically to push debris ***
- B. With bleach
- C. Circumferential

792) Mandibular 1st molar resemble :

- A. Mandibular primary 2dry premolar***

793) Functional cusp reduction:

- A. 1 - 1.5 mm**
- B. 2-3 mm**

794) Patient with healthy gingiva , upon insertion of perio probe , it should stop at :

- A. Most coronal of junctional epithelium ***
- B. 1/3 of coronal of junctional epithelium
- C. 2/3 of coronal of junctional epithelium
- D. Most apical point of junctional epithelium

795) Regarding incipient caries :

- A. Doesn't affect the pulp
- B. Surface zone relatively ***
- C. Spread in enamel more than dentine

796) By establishing CPR. You most :

- A. Establish unresponsiveness ***
- B. Determining air way is open

797) Radiolucncy in interradicular is:

- A. Furcational lesion ***

798) Most common cause of malocclusion :

- A. early loss of primary teeth***

799) Pedo pt. , gray teeth , narrow at apex , easily detached enamel probing (under pressure) :

- a. Amelogenesis
- b. Dentinogenesis ***

800) Although it's caries test , sdyn's test measures :

- A. Amount of acid producing microorganism ***
- B. PH of saliva
- C. Undetected caries lesion
- D. Amount of acid producing by each bacteria

801) Microbes produced by root canal bacteria is :

- A. Dentine by bacteria
- B. Collagenase by bacteria
- C. Phosphate by fibroblast
- D. All of the above ***

802) Osteomyelitis is more common in :

- A. Maxilla
- B. Mandible ***
- C. Zygoma
- D. Condyle

803) Scientific paper evaluated by all except :

- A. Sample size
- B. Rarely sample ***
- C. Type of study
- D. Study is original

804) Research study :

- A. Not benefit for high risk
- B. Not intervene study ***

805) Ethics in research include all except :

- A. Protection of your data
- B. No need for concert signature ***
- C. Protection from physical harm



OZIDENT

806) Pregnant women x-ray include all except :

- A. Sensitive x-ray
- B. Calibrate beam cone
- C. Use computer x-ray
- D. Short PID , bisecting ***

807) Trauma to upper central primary teeth 4 years child , the color become yellowish , the parents advise by :

- A. Pulp dead
- B. The pulp will be narrow and the canal will more calcified
- C. The root will resorbed normally
- D. A & B
- E. B & C ***
- F. All of the above

808) Perio-Endo lesion 1st ttt :

- A. Scaling & root plane
- B. RCT ***

809) Proximal caries restricted to enamel should be :

- A. Only under vision
- B. Intensive preventive measure ***
- C. GI restoration
- D. Bottom of pocket bone removal

810) Determination of diseased periodontal pocket the pt. compliance :

- A. Deep pocket ***
- B. Attached gingiva

811) Severe spontaneous pain of tooth have direct pulp capping , pt. complain from pain with hot that lasting :

- A. Irreversible pulpitis***

812) Onlay restoration:

- A. larger than amalgam restoration ***
- B. smaller than amalgam
- C. same as amalgam
- D. depend on caries extension

813) The most common type of odontogenic cyst is the:

OR

The most common type of inflammatory odontogenic cyst is:

- A. Dentegirous cyst.
- B. Periapical cyst. ***
- C. Odontogenic keratocyst.
- D. Residual cyst.

* Periapical cyst = Radicular cyst = Dental cyst.

814) The most common type of developmental odontogenic cyst is the:

- A. Dentegirous cyst. ***
- B. Periapical cyst.
- C. Odontogenic keratocyst.
- D. Residual cyst.

* The most common odontogenic cyst is the preiapical cyst (radicular cyst / dental cyst).

* The second most common odontogenic cyst is the dentigerous cyst (follicular cyst).

* The third most common odontogenic cyst is the keratocyst (primordial cyst).

815) Pt. with Mesial dark area of other caries & good oral hygiene ttt. :

- A. Observation
- B. Fluoride
- C. Restore with amalgam
- D. Restore with composite

816) Enamel rods form the main structure of enamel, they extend from the DEJ toward the dental pulp :

- A. true
- B. false ***

817) Acquired pellicle :

- B. Cell- free structure less organic adhere to tooth structure***
- C. Protect , reduce friction & help in remind
- D. Contain bacteria by products
- E. All of the above
- F. A + B

818) When we start to brush the teeth :

- a. From the first tooth eruption***
- b. 2 years
- c. 3 years
- d. 4 years

819) The acceptable or normal pt. rate of birthing in min. :

- a. 10
- b. 15
- c. 20**
- d. 30**

820) All are periodontal non-motile bacteria except :

- A. P. Gingivalis
- B. P. intermediate
- C.rectus
- D. A.A contain E coli , spirochetes ***

821) Cusp choosing by amalgam :

- a. tripling of cusp by amalgam***

822) Trauma in upper central with no pulp hyperemia :

- a. More intruded
- b. Congestion pulp
- c. Cut blood supply to the pulp
- d.

823) Canine you want to do root coverage using (lanzer's) tech. what is this tech. :

- a. Full thickness flap with spilt***

824) Unilateral bruxism include eye , nose , maxilla ,zygoma and discharge of nose tear eye , onset pain for 30 min pt. suffering from what :

- a. Naso pharyngeal neuralgia
- b. ophthalmic neuralgia
- c. ?

825) Change toothbrush every time for what or why the doctor recommends change toothbrush from time to time :

- a. To remove food accumulation
- b. To remove dental plaque
- c. ?

826) Lingual nerve is :

- a. Branch of facial n.
- b. Branch of mandibular n.
- c. Supply submandibular gland
- d. Both b and c ***

827) Mild tetracycline staining :

- a. Microabrasion
- b. Bleaching***

828) What of the material is not noble :

- a. Copper ***

829) Fractured tooth to alveolar crest what is the best way to produce ferrule effect :

- a. Extrusion with orthodontics ***
- b. Crown lengthening
- c. Restore with amalgam cone sub gingival

830) 22y old have mamillouge anterior teeth what is the cause :

- a. Amelogenesis
- b. Normal finding
- c. Sever crowding ***

831) Maxillary upper molar with grossly decade what is forceps we use :


- a. No. 1
- b. No. 17
- c. No. 23
- d. No. 88

832) Intra radicular RCT which irrigation :

- a. Saline
- b. Co oh
- c. EDTA
- d. Chlorhexidine

833) When we make denture for edentulous pt. you should compensate what :

- a. Compensate retention and stability ***



834) General information porcelain etchant is :

- a. 9.5 % buffered hydrofluoric acid gel that must be handled
- b. 35 % phosphoric acid
- c. 4 % hydrophilic acid
- d. 4-10 % hydrophilic acid ***

835) Physiological rest in edentulous pt. is :

- a. Equal to V.D of occlusion
- b. Must be greater than V.D of occlusion

836) Class 2 Furcation involvement the ttt. with no graft regeneration what is the tech :

- a. Gide tissue regeneration ***

837) To differentiation bet. Acute preiapical abscess and acute Pulpal abscess by :

- a. X ray
- b. Palpation
- c. Vitality test ***

838) Dry mouth and multiple caries :

- a. Congenital absent of salivary gland
- b. Congenital absent of sweet gland

839) Which is not important during seating prosthesis :

- a. Alveolar bridge
- b. Incisive papilla
- c. Median palatine raphe
- d. Retro molar bade

840) Child with physical disability and highly un cooperative with not present in the plan :

- a. Behavior shaping
- b. Sending to home**
- c. Tight with board**
- d. TSD

841) What is the effect of retention of FPD :

- A. (taper of opposing preparation is 15 degree)
- B. (long span of FPD & 15 degree taperness of opposing)***

842) True or false (balanced occlusion on natural teeth)(on both side no position made)

- A. Both T
- B. Both F
- C. 1st T 2nd F
- D. 1st F 2nd T***

843) Mouth was tacking () the () pigmentation of florosis :

- A. Central & canine
- B. Central & 1st molar & lateral ***
- C. Central & 1st molar & canine

844) Design of the occlusion in child :

- A. Mesio buccal cusp
- B. Distal buccal cusp of lower 2nd ***
- C. (Distal of 1st molar)

845) (Differentiation of epithelial by) :

- A. Loss of ***

846) Pt. has a bacterial disease after examination the doctor has to wash his hand using soap :

- A. With alcohol ***
- B. Non alcoholic
- C. Plain soap
- D. (either alcohol)

847) Old pt. have swelling in parotid gland, firm non tender on ex. The histopathology 2 raw of epith. Cells:

- a. adenoid cystic carcinoma***

848) Movement of polymorphoneutrophils bet. Gap blood vessel :

849) Main characteristic of well differentiated keratinocytes :

850) Histology of submandibular swelling :

Good luck...